

# **Anaplastic Astrocytomas: A Review of Biology and Treatment**

## **Marc C Chamberlain, MD**

University of Washington/ Fred Hutchinson Cancer Research Institute  
Departments of Neurology and Neurological Surgery  
Division of Neuro-Oncology

## **Sajeel A. Chowdhary, MD**

University of South Florida/ Moffitt Research Institute and Cancer Center  
Department of Interdisciplinary Oncology  
12902 Magnolia Drive  
Tampa, FL 33612  
Telephone: (813) 745-4251  
Fax: (813) 975-3713  
E-mail: Sajeel.Chowdhary@moffitt.org

## **Michael J Glantz, MD**

University of Utah/ Huntsman Cancer Center  
Departments of Oncology and Neurosurgery  
200 Circle of Hope, Suite 2100  
Salt Lake City, UT 84112-5550  
Telephone: (801) 585-0270  
Fax: (801) 585-0159  
E-mail: Michael.Glantz@hci.utah.edu

## **Corresponding author:**

## **Marc C Chamberlain, MD**

University of Washington  
Department of Neurology and Neurological Surgery  
Division of Neuro-Oncology  
Fred Hutchinson Cancer Research Institute  
Seattle Cancer Care Alliance  
825 Eastlake Ave E  
PO Box 19023, MS G-6800  
Seattle, WA 98109-1023  
Tel: (206) 288-8280  
Fax: (206) 288-2000  
E-mail: chambemc@u.washington.edu

**Key Words:** Anaplastic Astrocytoma; primary brain tumor; malignant glioma

**Abstract:**

Anaplastic astrocytomas (AA), World Health Organization (WHO) grade III gliomas, comprise 10-15% of all glial neoplasms. Currently the only factors that have been shown to influence prognosis in patients with AA are the age and Karnofsky performance status (KPS). Attempts have been made to identify biological prognostic factors for response to therapy and clinical outcome as well as potential targets for new therapies. The most important predictor of response to therapy and survival in AA tumors is the presence or absence of the 1p19q co-deletion, a translocation that defines a subset of oligodendroglial tumors and anaplastic oligodendrogliomas in particular. A further likely prognostic biomarker is the methylation status of O<sup>6</sup> – methylguanine – DNA – methyltransferase gene (the predominant DNA repair enzyme following alkylator-based chemotherapy induced injury). Because of a paucity of clinical trials specifically in patients with AA, most patients receive TMZ-containing regimens, based on data acquired from patients with glioblastoma multiforme. At present, there are no cooperative group trials being conducted for the adjuvant treatment of AA though several randomized trials have been proposed. Evidence-based management of patients with AA supports maximum safe resection followed by involved-field radiotherapy for newly diagnosed patients, and TMZ for recurrent disease. This treatment paradigm varies considerably from actual practice.

## **Introduction:**

The treatment of AA as for all high-grade gliomas (HGG) is unsatisfying. Current therapies are only modestly effective, and there is a limited consensus on therapy for either initial treatment or recurrent disease. Treatment for newly diagnosed patients includes surgery, chemotherapy, radioactive implants, stereotactic radiotherapy, and targeted therapy [1-20]. Chemotherapy and re-operation for recurrent AA is of modest benefit, primarily because response durations are short. In an analysis of eight institutional phase 2 studies of chemotherapy for recurrent high-grade gliomas, Wong reported that response rates in recurrent anaplastic gliomas were 14% and progression free survival at 6 months was 31% [13]. The most active first and second line agents are the nitrosoureas (e.g. carmustine (BCNU) and Lomustine (CCNU)), temozolomide (TMZ), procarbazine, cis-retinoic acid, irinotecan (CPT-11) and cyclophosphamide [1-4, 8-20, 23-29].

## **Pathology**

AA most often involve the white matter of the cerebral hemispheres, but may occur in other regions of the central nervous system as well [30,31]. In general, increased mitotic activity (implied, for example, by an increased Ki-67 or MIB1 index) characterizes anaplastic, or grade III tumors while endothelial proliferation and necrosis define the glioblastoma multiforme (GBM) or grade IV tumors. Anaplastic astrocytomas tumors are composed of cells with elongated or irregular, hyperchromatic nuclei and eosinophilic, glial fibrillary acidic protein (GFAP)-positive cytoplasm. In contrast, anaplastic oligodendrogliomas (AO) have rounded nuclei, often with perinuclear halos, calcification and delicate, branching blood vessels. Anaplastic oligoastrocytomas (AOA) have histological features of both astrocytic and oligodendroglial tumors. All anaplastic

gliomas can have significant regional heterogeneity and the tumors are graded histologically according to their most anaplastic appearing areas [30]. AA may arise from grade II diffuse gliomas (whether recognized clinically or not). These tumors, which are more common in younger patients, have been termed "secondary" (Figure 1). Most AA in adults however arise *de novo*, without a history of a prior lower-grade tumor. These have been termed "primary", and are more common in older patients. Contrasting molecular as well as clinical profiles distinguish primary and secondary AA (Fig 1 [32-36]). Some of these molecular changes may represent potential targets for future gene or targeted pharmacological therapies. Malignant gliomas are believed to contain multipotent tumor stem cells that are responsible for populating and repopulating the tumors [37, 38]. These tumor stem cells may be transformed variants of normal neural progenitor cells. The existence of these tumor stem cells may have therapeutic implications, since therapies that do not ablate the relatively chemo- and radio-resistant tumor progenitor cells will be ineffective in eradicating the tumor.

### **Molecular oncology**

The formation and progression of diffuse gliomas is accompanied by activation of oncogenes, inactivation of tumor suppressor genes, abrogation of apoptotic genes and deregulation of DNA repair genes. Different constellations of genetic alterations are associated with specific types of malignant gliomas, with particular tumor grades, and with differential sensitivities to specific therapies [30, 32]. WHO grade II astrocytoma (low grade astrocytomas, LGA) is associated with two common genetic alterations; inactivation of the TP53 tumor suppressor gene and loss of chromosome 22q [30].

Although the specific gene on chromosome 22q remains to be identified, the TP53 gene has been extensively studied in gliomas. TP53 maps to chromosome 17p and encodes the p53 protein, which plays an integral role in a number of cellular processes, including cell cycle arrest, response to DNA damage, and apoptosis. Inactivation of the TP53 gene, usually due to mutation of one allele and chromosomal loss of the remaining copy, occurs in about one-half of astrocytomas and about one-third of AA [34, 39]. The TP53 mutations are primarily missense mutations and target the evolutionarily-conserved domains in exons 5, 7 and 8. Particular mutational hot-spots include codons 175, 248 and 273, in which C to T transitions are most likely the result of spontaneous deamination of 5-methylcytosine residues. These mutations affect nucleotide residues that are crucial for DNA binding, presumably leading to loss of p53-mediated function [1].

The transition from LGA to AA is associated with inactivation of tumor suppressor genes on chromosomes 9p, 13q and 19q [30]. Loss of chromosome 13q, which includes the retinoblastoma (RB) gene locus, occurs in approximately one-third of higher-grade astrocytic tumors [30]. Approximately two-thirds of AA demonstrate homozygous deletions of the region of chromosome 9p that include the CDKN2A and CDKN2B genes. In general, alterations of RB, CDKN2A and the CDK4 gene are mutually exclusive in GBM [40]. Malignant progression to GBM is also associated with inactivation of the PTEN tumor suppressor gene on chromosome 10, and amplification of the EGFR gene [41]. Chromosome 10 loss occurs in 60 to 85% of GBM, with approximately 25% of cases also having PTEN mutations [42]. The EGFR gene is amplified in approximately 40% of all GBM (but is uncommon, <10% of cases, in AA), resulting in overexpression of EGFR, a transmembrane receptor tyrosine kinase [39].

Approximately one-third of GBM with EGFR gene amplification also have gene rearrangements, some encoding truncated, constitutively active mutants. By far the most common of these is known as variant III (EGFRviii) [1]. EGFR gene amplification-associated GBM may arise *de novo*, or rapidly from a preexisting tumor [32,39]. In contrast, EGFR gene amplification almost never occurs in GBM with TP53 mutation or loss of chromosome 17p [39]. Overall, approximately one-third of GBM have TP53 inactivation, one-third have EGFR gene amplification, and one-third have neither of these changes. The glioma pathway that includes TP53 inactivation most often involves progression from a lower-grade astrocytoma, the so-called secondary AA or GBM (Figure 1). These high-grade gliomas tend to occur in significantly younger adults than AA or GBM with EGFR gene amplification. In contrast, GBM with EGFR amplification typically occur in older patients who do not have a history of preceding lower-grade astrocytoma, so-called primary high grades [40, 41].

The ability of molecular genetic techniques to reveal biological heterogeneity in AA and GBM raises the possibility that new approaches to diagnosis and treatment will be based on objective biological parameters (Figure 2). A variety of growth factors or oncogenes, are overexpressed in AA and high grade gliomas and thus provide a growth advantage to neoplastic cells. In general, glioma cells express both the ligand growth factor and its receptor, setting up an autocrine/paracrine growth-promoting loop. Some growth factors are highly expressed in low-grade as well as high-grade gliomas, whereas others are primarily overexpressed only in GBM. A list of the growth factors and growth factor receptors involved most commonly in malignant gliomas includes [30]: platelet-derived growth factor (PDGF); epidermal growth factor receptor (EGFR); basic fibroblast growth

factor ( $\beta$ FGF, FGF-2); transforming growth factor (TGF)- $\alpha$ ; and insulin-like growth factor (IGF)-1. PDGF and EGFR have been most studied. The A chain of the PDGF ligand is expressed in the vast majority of diffuse astrocytic tumors, along with its cognate alpha receptor, and is therefore viewed as an early change in astrocytoma tumorigenesis [43]. Other growth factors like EGFR, however, are primarily upregulated only in GBM, suggesting that these molecules are involved in progression rather than initiation of gliomas [30]. The mechanisms for growth factor overexpression also vary between growth factors. For example, as noted above, EGFR overexpression arises as a result of gene amplification, whereas PDGF and PDGF receptor overexpression occurs at the transcriptional level. Progression through the normal cell cycle is meticulously controlled. Glioma cells, however, develop means for eliminating such control, giving them a growth advantage. As expected, many of the genetic defects in growth regulatory molecules occur preferentially in malignant, rather than low grade, gliomas. In fact, the transition from the more slowly growing grade II gliomas to the aggressive, anaplastic, grade III lesions is attended by cell cycle deregulation; hence, the histological appearance of mitotic activity in grade III gliomas.

The cell cycle checkpoint that has received the most attention has been the G1-S phase transition [43]. One of the major pathways controlling this checkpoint involves the p16, cyclin dependent kinase (CDK)-4, cyclin D, and pRB (retinoblastoma) proteins [30]. The protein encoded by the RB gene, pRB, is crucially involved in cell-cycle arrest; the loss of pRB function in gliomas thereby removes an important brake on the cell cycle. One upstream mediator of pRB function is the p16 product of the CDKN2A gene (also called p16INK4A) on chromosome 9p, a tumor suppressor inactivated in a number of human

tumors. 5 (Figure 2) p16 inhibits the cyclin-dependent kinase complex that regulates RB. The vast majority of glioma cell lines and two-thirds of high-grade primary astrocytomas show homozygous deletions of chromosome 9p that include this gene. It is likely that these deletions result in loss of expression of the p16 and p14ARF transcripts from CDKN2A and the p15 transcript from the nearby CDKN2B (also called MTS2 [multiple tumor suppressor 2]), resulting in loss of multiple cell cycle control checkpoints and greater proliferation [30]. The CDK4 (cyclin dependent kinase 4) gene is amplified and overexpressed in 10 to 15 percent of high-grade astrocytomas. CDK4 itself is regulated by p16 and inactivates pRB through phosphorylation. Thus, nearly all high-grade tumors have impairments of this single critical cell cycle control pathway. It is likely as well that less profound defects in cell cycle regulation occur in lower-grade gliomas; for instance, TP53 gene mutations may affect both the G1-S and G2-M checkpoints.

Most normal cells activate cell death (apoptotic) pathways in response to DNA damage or abnormal proliferation. Thus AA tumor cells must develop means not only for increasing proliferation but for abrogating apoptosis as well. A number of genes implicated in malignant glioma pathogenesis have roles in apoptosis pathways, most notably TP53. TP53 mutations may impede the normal glial apoptotic response that would otherwise follow growth factor overexpression in low-grade gliomas, allowing further tumorigenesis to occur [30]. A cardinal feature of diffuse low-grade gliomas is their nearly universal progression to higher grade lesions over time (Table 1). Such malignant progression is related to the emergence of more malignant clones. The presence of genomic instability, a feature of many tumors, encourages further genomic damage, thus allowing the eventual selection of more malignant clones. TP53 has been

dubbed "the guardian of the genome" because of its role in protecting cells from DNA damage. Mutations of TP53 may therefore lead to tumor progression through genomic instability [30]. Interestingly, patients with syndromes of genomic instability, such as the hereditary non-polyposis colorectal cancer syndromes, have an increased susceptibility to malignant gliomas (Turcot syndrome) [30]. Another feature of malignant gliomas is their diffuse infiltration of the surrounding neuropil. Considerable effort has been dedicated toward elucidating the mechanisms of glioma cell invasion [44]. The expression of several extracellular matrix molecules and cell surface receptors may modulate signal transduction pathways and influence invasion and migration in high-grade gliomas. These include cytoskeletal proteins; signaling molecules that mediate interactions between the external milieu and the cytoskeleton; cell surface receptors involved in cell migration such as transmembrane adhesion molecules (integrins); and components of extracellular matrix, including proteases [44].

A dramatic sequence of vascular changes occurs in the transition from AA to GBM, a fact that is reflected in the intense, often ring-like contrast enhancement that surrounds rapidly growing tumors [45]. Malignant gliomas are highly vascular tumors, and the histological presence of microvascular proliferation indicates that the tumor is of high-grade. Angiogenic molecules have been found in malignant gliomas, primarily in glioblastoma [34, 45]. The most clearly implicated is vascular endothelial growth factor (VEGF), an endothelial cell mitogen that is expressed most often adjacent to areas of necrosis, and is absent in grade 2 astrocytomas. This suggests that the malignant progression from low-grade astrocytoma to GBM includes an "angiogenic switch." VEGF receptors are expressed by tumor endothelial cells, setting up a paracrine loop in

which the tumor cells encourage vascular proliferation. The microenvironment is thus of importance in glioblastoma, with regions of neovascularization often surrounding zones of necrosis. Another angiogenic molecule with increased concentration in malignant gliomas is PDGF. The PDGF beta receptor is present on endothelial cells, implying a similar paracrine effect of PDGF on endothelial cells [34, 45]. One of the main triggers for tumor angiogenesis is believed to be the physiologic response to hypoxia, which induces increased transcription of the VEGF gene by the hypoxia-inducible factor (HIF) family of transcription factors [46-48]. An intriguing hypothesis suggests that thrombosis of small blood vessels, perhaps mediated by tissue factor, induces islands of micronecrosis, and that these events initiate the hypoxic and angiogenic cascades [46, 47].

To date, molecular markers have been of demonstrated usefulness in predicting response to chemotherapy in only three settings in gliomas: 1p and 19q loss in oligodendroglial tumors (i.e. AO and AOA), MGMT in TMZ response in gliomas in general, and the EGFR-PI3 kinase pathways in response of GBM to specific EGFR inhibition. MGMT is an enzyme that is responsible for DNA-repair following alkylating agent chemotherapy. In the course of tumor development, the MGMT gene may be silenced by methylation of its promoter, thereby reducing the amount of MGMT present in the tumor cell, diminishing repair of DNA damage, and increasing the potential effectiveness of alkylator-based chemotherapy. Several clinical studies have indicated that such promoter methylation is associated with an improved survival in patients receiving adjuvant alkylating agent chemotherapy [48-50]. The importance of MGMT gene status was illustrated in a trial evaluating adjuvant TMZ following surgery and radiotherapy for

GBM. Survival was significantly prolonged among those in whom the MGMT promoter was methylated, regardless of whether or not TMZ was given, suggesting MGMT methylation predicts for response to alkylator-based chemotherapy(HR 0.45, 95% CI 0.32-0.61) [50].. The benefit of adjuvant TMZ was most pronounced for patients with methylated MGMT (median survival 21.7 versus 15.3 months in those treated with radiotherapy alone). In patients whose tumors did not have methylation of MGMT, the benefit was smaller and not statistically significant.

### **Clinical Manifestations**

The clinical manifestations of anaplastic astrocytic tumors (AA, non-deleted AO and AOA) are dependent upon the location and size of the lesion. High-grade astrocytomas produce symptoms and signs by local brain invasion, compression or irritation of normal brain or by increased intracranial pressure (ICP) (Figure 3). Increased ICP may lead to the classic clinical triad of headache, nausea, and papilledema. In patients followed by the Glioma Outcomes Project (147 Grade III and 418 Grade IV), headache and seizure were the most common presenting symptoms [51]. Headache occurred in 53 to 57% of cases. Seizures were present at diagnosis in 56% of patients with grade III lesions, compared with 23% of those with grade IV lesions. Other symptoms seen at presentation in 20% or more of patients included memory loss, motor weakness, visual disturbance, language deficit, and cognitive and personality changes. The frequency of more advanced neurological deficits and findings were substantially lower in this study than in older series. This likely reflects earlier diagnosis due to the availability of modern radiological imaging techniques. Patients with high grade malignant astrocytoma may also present with the acute onset of symptoms secondary to intracranial hemorrhage or tumor cyst

formation [52]. AA and other malignant astrocytomas rarely present clinically with meningeal dissemination, but autopsy studies (where up to 21% of patients demonstrate leptomeningeal involvement) suggest that this is a relatively frequent event. [53]. Common presenting symptoms of meningeal gliomatosis are back pain with or without radicular symptoms, mental status changes, cranial nerve palsies, myelopathy, cauda equina syndrome, and headache with symptomatic hydrocephalus [53]. Survival is short in patients who develop this complication (median 3.5 months in one series) [54]. Malignant astrocytoma rarely metastasizes systemically to the viscera, lymph nodes, skeleton, and bone marrow [54].

### **Diagnosis**

The diagnostic evaluation for a patient presenting with recent onset of headaches, localized weakness or seizures usually begins with an imaging procedure, often a non-contrast CT, followed by a contrast-enhanced MRI. Compared with computed tomography (CT), MRI is much more sensitive and provides greater anatomic detail useful for surgical and radiotherapy planning [55, 56]. MR spectroscopy FDG-PET, echo planar MRI, and functional or diffusion tensor MRI are additional studies that may have clinical utility in specific situations. Cerebral angiography is rarely utilized in the routine work-up of these patients.

Malignant astrocytomas are usually hypointense on MRI T1-weighted images. Heterogeneous enhancement is typical following contrast infusion. Alternatively, there may be areas of solid contrast enhancement within a more diffuse or serpiginous enhancement pattern, or the lesion may show a totally solid pattern of enhancement. Most

commonly, anaplastic gliomas enhance in a ring-like pattern that is variable in thickness, with small finger-like projections extending toward the necrotic center or away from the enhancing rim. CT scans may miss structural lesions particularly in the posterior fossa, or nonenhancing lesions. On pre-contrast CT scans, astrocytomas are often hypodense or isodense compared to normal brain. If the lesion responsible for the inciting symptoms is small, or the associated mass effect is subtle, a stroke or even a normal study may be diagnosed. After contrast infusion, enhancement patterns are similar to those seen with MRI, with contrast enhancement allowing distinction between tumor and surrounding edema. Contrast enhancement on MRI or CT is not specific for tumor and can be due to any process that disrupts the blood-brain barrier, for example, abscess and subacute stroke. In addition, approximately 30% of patients with AA and 4% of patients with GBM lack contrast enhancement on either CT or MRI [56]. Preoperative tumor glucose utilization, as determined by FDG-PET (positron emission tomography), has been evaluated in the preoperative evaluation and post-treatment follow-up of patients with malignant glioma. Glucose utilization in high-grade gliomas does appear to correlate with tumor grade and with patient survival. The eventual diagnosis of anaplastic astrocytic tumors is provided by stereotactic biopsy or preferably maximal safe resection as defined by the NCCN guidelines [57]. Maximal safe resection not only provides tissue for diagnosis but in addition palliates mass effect, allows improvement in tumor-related signs and symptoms and may increase survival by several mechanisms (Figure 4).

## **TREATMENT**

### *Adjuvant*

Prados in a seminal paper reporting on the outcome of patients with AA, concluded that median survival is approximately 3.3 years, that young age and high Karnofsky performance status have a positive influence on survival, and that salvage therapies may extend survival after the onset of tumor progression for nearly a year [17] (Table 2, 3). In another analysis of anaplastic gliomas (predominantly AA) by Tortosa, median overall survival was 29 months with a 5-year probability of survival of 38% (18). Prados also reviewed the Radiation Therapy Oncology Group (RTOG) database and compared patients with newly diagnosed AA treated according to protocol with either BCNU (n=257) or PCV {procarbazine, CCNU and vincristine} (n=175) adjuvant chemotherapy following surgery and conventional external beam radiotherapy [2] (Table 4). The stratified analysis showed no improvement in survival by treatment group and there did not appear to be any survival benefit to PCV adjuvant chemotherapy. The Cox model identified only age, performance status and extent of surgery as important variables influencing survival. The authors concluded that the inclusion of chemotherapy in the adjuvant treatment of newly diagnosed AA, though common practice, could not be endorsed without a randomized study. Laramore reviewed the RTOG database of 163 patients with newly diagnosed AA treated in sequential studies with RT only, RT + nitrosourea-based chemotherapy or RT + heavy particle neutron based radiotherapy and showed a decrement in survival with additive therapies (median survival 3, 2.3 and 1.7 years respectively)[21]. Encouraged by a small study comparing RT+BCNU to RT+PCV (which showed improved survival in the PCV arm), the Medical Research Council Brain Tumor Working Group conducted the largest randomized trial of HGG comparing

patients treated with radiotherapy alone (RT) to RT+PCV chemotherapy [1]. Of 594 eligible patients, 17% (113) had AA histology. There was no statistically significant difference in median survival (13 month median survival for the RT only group vs. 21 months in the RT+PCV group) however a 5.5% increase in 2-year survival was seen for the PCV arm (2-year survival rate 37% RT only vs. 42.5% RT+PCV). Levin, building upon prior work, reported on the largest prospective randomized trial of newly diagnosed anaplastic gliomas (n=249) comparing RT+PCV to RT+PCV+DFMO (difluoromethylornithine, an ornithine decarboxylase inhibitor) [8, 19]. Approximately 75% of all patients had AAs, and in this histologic group, median survival favored the PCV+DFMO arm (71.2 months vs. 46 months; P value = 0.035). The investigators concluded that the PCV+DFMO arm is superior to PCV alone and suggests a clinical benefit for adjuvant chemotherapy for AA. Prados reported on the RTOG 9404 randomized phase III trial in newly diagnosed AA comparing RT+PCV to RT+PCV+ the halogenated pyrimidine, BUdR (a radiosensitizing agent) and showed no survival advantage with the inclusion of BUdR (median survival 4.6 years for the BUdR group vs. 4.1 years for the non-BUdR group, p = 0.61 ) [22]. In a recent meta-analysis by the Glioma Meta-Analysis Trialists Group of 12 randomized trials, adjuvant chemotherapy improved 2-year survival by 6% in AA (31% vs. 37%) [9]. The above-mentioned studies suggest a potential benefit for the inclusion of chemotherapy in the adjuvant treatment of AA although the choice of adjuvant chemotherapy has evolved since publication of this meta-analysis. Since the introduction of TMZ into clinical practice in 2000, TMZ has largely replaced BCNU as the adjuvant chemotherapy of choice for patients with newly diagnosed AA, based on its efficacy in the treatment of recurrent AA () and in newly

diagnosed GBM (when used concurrent with and then following radiation therapy , and because of its relatively modest toxicity [14, 58]. Unfortunately, analogous data supporting the adjuvant use of TMZ in AA is lacking, and extrapolating treatment strategies for GBM to AA is problematic. The RTOG and the Southwest Oncology Group (SWOG) initiated a randomized trial comparing adjuvant TMZ to BCNU in newly diagnosed patients with AA, the first randomized trial to directly compare TMZ to BCNU [20]. Unfortunately the trial closed prematurely due to poor accrual and to date no data regarding outcome has been reported.

Two recently reported cooperative group trials, one performed by the RTOG and the other by the European Organization for Research and Treatment of Cancer (EORTC), evaluated adjuvant chemotherapy in the treatment of AO/AOA (Table 4) [59, 60]. Both trials utilized PCV although administration of PCV was both neoadjuvant and dose-intense in the RTOG trial and adjuvant (standard dose and schedule) in the EORTC trial. In neither study was PCV therapy associated with improved overall survival. A benefit was seen with respect to progression free survival in the RTOG trial, but only in patients with 1p19q co-deleted AO/AOA. In addition, both trials demonstrated by molecular analysis that 25% (EORTC) to 50% (RTOG) of histologically defined AO/AOA contained the 1p19q co-deletion. This group of patients (1p19q co-deleted) had substantially improved overall and progression free survival irrespective of treatment (median overall survival >7 years). In contrast, partially or non-1p19q deleted AO/AOA behave like AA/GBM, with median survivals ranging from 2-3 years (59, 60). Both cooperative group trials concluded that 1p19q co-deleted AO/AOA is a distinct tumor type, separable from other anaplastic gliomas and deserving of histology- and molecular

biology-specific clinical trials. The studies also concluded that genotyping of AO/AOA is not recommended outside of clinical trials, since therapy does not differ based on genotype results.

Overall, these trials fail to provide compelling evidence in support of adjuvant chemotherapy in the treatment of newly diagnosed AA, and the evidence-based standard of care remains maximal safe resection followed by involved-field radiotherapy (Table 5). The EORTC has proposed a 2x2 factorial study (the CATNON trial) to address this issue in patients with anaplastic gliomas that are either 1p or 19q intact (Table 6). This ambitious study will provide needed clarity with respect to the benefit of adjuvant chemotherapy in the treatment of newly diagnosed AA.

### *Salvage*

How best to manage recurrent AA remains ill-defined notwithstanding nearly a dozen studies (Table 7). Most studies however are single arm Phase II nonrandomized trials comparing outcome to historical controls. In an analysis of eight institutional phase 2 studies of chemotherapy for recurrent high-grade gliomas, Wong reported a response rate in recurrent AA (n=150) of 14% and a progression free survival at 6 months of 31% [11]. Yung in a Phase 2 trial of TMZ for recurrent AA, AO or AOA (n=111 after central pathology review) demonstrated a 6-month progression free survival of 46%, an objective neuroradiographic response rate of 35% and an overall survival of 13.6 months [14]. Sixty percent of patients in this study had received adjuvant BCNU, 18% underwent re-operation at time of recurrence and median time to tumor recurrence was 15.2 months. Brem reported on a randomized trial of patients with recurrent high-grade glioma (HGG) and compared surgery with or without placement of biodegradable

BCNU-impregnated polymers (Gliadel) [24]. Thirty-one of the 222 patients (14%) enrolled in this study had AA. The study demonstrated a 35% improvement in overall survival (31 weeks vs. 23 weeks and a 50% increase in 6-month progression free survival (64% vs. 44%). Unfortunately, a separate analysis of the AA group was not reported. These results suggest that when a near complete resection can be performed, Gliadel is an effective therapy for patients with recurrent AA or GBM. Unfortunately, only a minority of patients with recurrent AA are candidates for re-operation. Therefore, the majority of patients desiring further therapy are offered chemotherapy (Table 7). Yung evaluated 13-cis-retinoic acid (cRA) in a small phase II study of 28 patients with recurrent AA and showed an 11% response rate and 31 week median survival [26]. Building on the apparent efficacy of both TMZ and cRA, Jaeckle reported on the combination of TMZ and cis-retinoic acid (Accutane) for recurrent HGG of whom 22% were chemotherapy naïve [6]. A 46% 6-month progression free survival and 47-week median overall survival was seen amongst the 28 patients with AA. Levin reported on a study of 44 patients with recurrent AA using DFMO (enflornithine) and reported a median survival of one year, with 45% of patients experiencing either a radiographic response or stable disease [23]. In another trial by Levin, the drug combination of TPCD (6-thioguanine, procarbazine, CCNU and dibromodulcitol) was used in 38 patients with recurrent AA with a 34% response rate and 50 week median survival [25]. Chamberlain in a series of trials of patients with recurrent AA, showed 22-23% response rates to either cyclophosphamide or CPT-11 in patients refractory to TMZ [27-29]. The 6-month PFS was 40% and median survival was 28 weeks. Most remarkably, in a small cohort of patients with recurrent AA (n=9) treated with the combination of CPT-11 and bevacizumab, a 67% response rate and

56% 6-month progression free survival was reported by Vrendenburgh [62]. Two other investigational treatments (both targeted therapies) for recurrent HGG, the pan-VEGF receptor inhibitor, AZD2171, and the anti-integrin, cilengitide, are presently under active study [63, 64]. How to incorporate these treatments into the care of patients with recurrent AA outside of investigational trials is unclear though increasingly bevacizumab is being utilized based upon scant data. The British National Cancer Research Institute has proposed a randomized trial for recurrent AA comparing TMZ (either the standard 5/28 dose schedule or the dose dense 21/28 dose schedule) to PCV. As an alternative to chemotherapy, Combs and Ulm, in separate studies, have suggested that reirradiation (with either single fraction or fractionated stereotactic radiotherapy) may be beneficial in select patients with histologically confined recurrent gliomas [65, 66]. Amongst 42 patients treated by Coombs with recurrent AA, median survival was 16 months after reirradiation.

## **CONCLUSIONS**

Management of AA remains uncertain due to a paucity of clinical trials and resulting lack of a standard of care. Despite the widespread use of concurrent and sequential TMZ in newly diagnosed AA (predicated on the successful use of this approach in patients with GBM) there is no compelling data to support adjuvant chemotherapy for AA. Therefore, outside of an investigational trial, the best evidence-based initial treatment of AA entails maximum safe resection followed by involved-field radiotherapy [57] (Table 5). Therapy at recurrence might include re-resection if clinically feasible and implantation of Gliadel wafers in patients with minimal residual disease. Following surgery or in patients not considered for re-operation, SRT could be

considered for patients with small volume tumors. Alternatively, chemotherapy, most often TMZ, is reasonable. The current enthusiasm for CPT-11 and bevacizumab needs to be tempered by recognition that there is very limited data regarding recurrent AA. Clinical trials designed specifically for patients with AA are needed. In the meantime, most of contemporary therapy for AA is based on an uneasy extrapolation of treatment of other gliomas, particularly GBM.

### **EXPERT COMMENTARY**

Based on the literature, initial treatment of anaplastic astrocytoma (defined as WHO Grade III malignant gliomas without evidence of 1p19q co-deletion) entails maximum safe resection followed by involved-field radiotherapy. The administration of adjuvant chemotherapy though commonly prescribed lacks level 1 evidence and consequently is of unclear value. The administration of adjuvant chemotherapy to patients with anaplastic astrocytoma is based on two studies although neither specifically addressed the treatment of anaplastic astrocytoma. In two meta-analysis, a 5-6% benefit in survival was seen when adjuvant nitrosourea-based chemotherapy is administered. In both meta-analyses, anaplastic astrocytoma was a subset of the much larger group under study i.e. GBM. The second basis for the use of adjuvant chemotherapy in the initial treatment of anaplastic astrocytoma is derived from the EORTC trial of TMZ in the initial treatment of GBM which demonstrated a compelling benefit for patients with GBM and in particular MGMT silenced tumors. Despite the fact that this trial was conducted in patients with GBM only, the trial results have been extrapolated to the treatment of anaplastic astrocytoma. Pending the results of the randomized trial by the EORTC (the CATNON trial), the issue of adjuvant chemotherapy for anaplastic astrocytoma will remain

controversial and unsettled. In the recurrent setting there is very good evidence for the palliative effectiveness of multiple therapies including chemotherapy and in particular TMZ.

#### FIVE-YEAR VIEW

Two important trials regarding WHO Grade III malignant gliomas will be initiated next year and likely early but incomplete results will be available within 5-years. In the first trial mentioned above, CATNON and to be initiated by the EORTC, patients with newly diagnosed anaplastic astrocytoma lacking the 1p19q codeletion and following maximum safe resection will be randomized to RT alone or RT+TMZ. Following completion of RT, patients will again be randomized (2x2 factorial design) to TMZ for 12 cycles or observation. This trial will definitively determine the value of adjuvant TMZ in the initial management of anaplastic astrocytoma lacking the 1p19q codeletion. In the second trial (the CODEL trial), an intergroup trial with RTOG, NCCTG and EORTC, patients with 1p19q codeleted WHO Grade III malignant gliomas will be randomized (3 arms) following maximum safe resection to RT or primary TMZ or RT+TMZ. Likely early results will be available within 5-years to indicate whether adjuvant chemotherapy or primary chemotherapy with deferred RT results in benefit (either median overall or progression free survival). Lastly, it is likely that several targeted therapies will be integrated into the management of malignant gliomas in particular bevacizumab and cilengitide in either the adjuvant or recurrent setting.

## KEY ISSUES

- Anaplastic astrocytoma (10-15% of all infiltrative gliomas) appears biologically separable into two main categories defined by the presence or absence of the chromosomal 1p19q codeletion.
- Anaplastic astrocytomas without the 1p19q codeletion constitute the majority of WHO Grade III malignant gliomas and compared to Grade III malignant gliomas with the 1p19q codeletion have significantly shorter progression free and overall survival.
- There is no level 1 evidence indicating a value (as defined by survival) to adjuvant chemotherapy for WHO Grade III malignant gliomas regardless of 1p19q status.
- Despite the lack of evidence, most newly diagnosed Grade III malignant gliomas are treated with adjuvant chemotherapy.
- Two new trials, one for 1p19q nondeleted Grade III malignant gliomas (the CATNON trial) and another for 1p19q codeleted Grade III malignant gliomas (the CODEL trial) will initiate next year and clarify the role of adjuvant chemotherapy for these glioma subtypes.

## REFERENCES:

1. \*The Medical Research Council Brain Tumor Working Party: Randomized Trial of Procarbazine, Lomustine, and Vincristine in the Adjuvant Treatment of High-Grade Astrocytoma: A Medical Research Council Trial. *J Clin Oncol* 19, 509-518 (2001).  
A randomized trial of malignant gliomas comparing RT with or without PCV chemotherapy as initial therapy that demonstrated no benefit to adjuvant chemotherapy for either GBM or AA.
2. \*Prados MD, Scott C, Curran WJ, et al: Procarbazine, Lomustine, and Vincristine (PCV) Chemotherapy for Anaplastic Astrocytoma: A Retrospective Review of Radiation Therapy Oncology Group Protocols Comparing Survival with Carmustine or PCV Adjuvant Chemotherapy. *J Clin Oncol* 17, 3389-3395 (1999).  
A retrospective comparative study evaluating the effectiveness of adjuvant chemotherapy for AA demonstrating no survival differences.
3. Westphal M, Hilt DC, Bortey E., et al: A phase 3 trial of local chemotherapy with biodegradable Carmustine (BCNU) wafers (Gliadel wafers) in patients with primary malignant glioma. *Neuro-Oncol* 5(2),79-88(2003).
4. Prados MD, Levin V. Biology and treatment of malignant glioma. *Semin Oncology* 27(3 Suppl 6), 1-10(2000).
5. Gutin PH, Prados MD, Phillips TL, et al. External irradiation followed by an interstitial high activity iodine-125 implant "boost" in the initial treatment of malignant gliomas: NCOG Study 6G82-2. *Int J Radiat Oncol Biol Phys* 21,601(1991).
6. Loeffler JS, Alexander E, Shea WM, et al. Radiosurgery as part of the initial management of patients with malignant gliomas. *J Clin Oncol* 10(9), 1379-

1385(1992).

7. Prados MD, Gutin PH, Phillips TL, et al. Interstitial brachytherapy for newly diagnosed patients with malignant gliomas: The UCSF experience. *Int J Radiat Oncol Biol Phys* 24:593(1992).
8. Levin VA, Silver P, Hannigan J, et al. Superiority of Post-Radiotherapy Adjuvant chemotherapy with CCNU, Procarbazine, and Vincristine (PCV) over BCNU for Anaplastic Gliomas: NCOG 6G61 Final Report. *Int J Radiat Oncol Biol Phys* 18,321-324(1990).
9. \*\*Stewart LA. Chemotherapy in adult high-grade glioma: A systemic review and meta-analysis of individual patient data from 12 randomized trials. *Lancet* 359, 1011-1018(2002).  
One of two meta-analyses demonstrating a 5-6% improvement in overall survival with the inclusion of adjuvant chemotherapy in malignant gliomas.
10. Fine HA, Dear KB, Loeffler JS, et al. Meta-analysis of radiation therapy and without chemotherapy for malignant gliomas in adults. *Cancer* 71, 2585-2597(1993).
11. \*\*Wong ET, Hess KR, Gleason MJ, et al. Outcomes and prognostic factors in recurrent glioma patients enrolled onto phase II clinical trials. *J Clin Oncol* 17, 2572-2578 (1999).  
A retrospective evaluation of 8 clinical trials in patients with recurrent malignant gliomas demonstrating the value of progression free survival at 6-months and establishing benchmarks for subsequent trials.
12. Yung WKA, Mechtler L, Gleason MJ. Intravenous carboplatin for recurrent malignant gliomas: A phase II study. *J Clin Oncol* 9, 860 (1991).
13. Allen JC, Walker R, Luks E, et al. Carboplatin and recurrent childhood brain tumors. *J Clin Oncol*, 759-763(1987).

14. \*\*Yung WK, Prados MD, Yaya-Tur R, Rosenfeld SS, Brada M, et al. Multicenter Phase II Trial of Temozolomide in Patients with Anaplastic Astrocytoma or Anaplastic Oligoastrocytoma at First Relapse. *J Clin Oncol* 17, 2762-2771(1999).

The largest prospective trial of TMZ in the treatment of recurrent WHO Grade III malignant gliomas showing favorable palliative benefit.

15. Allen JC, Helson L. High-dose cyclophosphamide chemotherapy for recurrent CNS tumors in children. *J Neurosurg* 55, 749-756 (1981).
16. Longee DC, Friedman HS, Albright RE, Burger PC, et al. Treatment of patients with recurrent gliomas with cyclophosphamide and vincristine. *J Neurosurg* 72,583-588(1990).
17. \*Prados MD, Gutin PH, Phillips TL, et al. Highly Anaplastic Astrocytoma: A review of 357 patients treated between 1977 and 1989. *Int J Radiat Oncol Biol Phys* 23, 3-8 (1992).  
Another retrospective review of AA indicating no benefit to the inclusion of adjuvant chemotherapy.
18. Tortosa A, Vinolas N, Villa S, Verger E, Gil JM, et al. Prognostic Implications of Clinical, Radiologic, and Pathologic Features in Patients with Anaplastic Gliomas. *Cancer* 97, 1063-1071(2003).
19. Levin VA, Hess KR, Choucair A, Flynn PJ, Jaeckle KA, et al. Phase III randomized study of postradiotherapy chemotherapy with combination  $\alpha$ -difluoromethylornithine-PCV versus PCV for anaplastic gliomas. *Clin Cancer Res* 9,891-990(2003).
20. Chang SM, Seiferheld W, Curran W, Share R, Atk J, et al. Phase I study pilot arms of radiotherapy and carmustine with temozolomide for anaplastic astrocytoma (Radiation

Therapy Oncology Group 9813): implications for studies testing initial treatment of brain tumors. *Int J Radiat Oncol Biol Phys* 59, 1122-1126(2004).

21. Laramore GE, Martz KL, Nelson JS, Griffin TW, Chang CH, et al. Radiation Therapy Oncology Group (RTOG) survival data on anaplastic astrocytomas of the brain: does a more aggressive form of treatment adversely impact survival? *Int J Radiat Oncol Biol Phys* 17 (6), 1351-1356(1989).
22. Prados MD, Seiferheld W, Sandler HM, Buckner JC, Phillips T, et al. Phase III randomized study of radiotherapy plus procarbazine, lomustine, and vincristine with or without BUdR for treatment of anaplastic astrocytoma: final report of RTOG 9404. *Int J Radiat Oncol Biol Phys* 58, 1147-1152(2004).
23. Levin VA, Prados MD, Yung WKA, Gleason MJ, Ictech S, Malec M. Treatment of recurrent gliomas with enflornithine. *J Nat Cancer Instit* 84, 1432-1437(1992).
24. Brem H, Piantadosi S, Burger PC, Walker M, Selker R, et al. Placebo-controlled trial of safety and efficacy of intraoperative controlled delivery by biodegradable polymers of chemotherapy for recurrent gliomas. *Lancet* 345, 1008-1012(1995).
25. Levin VA, Prados MD. Treatment of recurrent gliomas and metastatic brain tumors with a polydrug protocol designed to combat nitrosoureas resistance. *J Clin Oncol* 10,766-771(1992).
26. Yung WKA, Kyritsis AP, Gleason MJ, Levin VA. Treatment of recurrent malignant gliomas with high-dose 13-cis-retinoic acid. *Clin Cancer Res* 2, 1931-1935(1996).
27. Chamberlain MC, Kormanik P. Salvage chemotherapy with taxol for recurrent anaplastic astrocytomas. *J Clin Oncol* 43, 71-78(1999).
28. Chamberlain M, Tsao-Wei D, Blumenthal D, Glantz MJ. Salvage chemotherapy

with CPT-11 for recurrent temozolomide-refractory anaplastic astrocytoma *Cancer* (in press) (2007).

29. Chamberlain MC, Tsao-Wei D, Groshen S. Salvage Chemotherapy with Cyclophosphamide for Temozolomide Refractory Anaplastic Astrocytoma. *Cancer* 106(1), 172-179 (2006).
30. Pathology and genetics of tumors of the nervous system. Presented at: *World Health Organization Classification of Tumours of the Nervous System, Editorial and Consensus Conference Working Group*. (Kleihues P, Cavenee WK, Eds), Lyon, France: IARC Press, 2007.
31. Ironside JW, Moss TH, Louis DN, et al. *Diagnostic Pathology of Nervous System Tumours*. London: Churchill Livingstone, (2002).
32. Louis DN, Pomeroy SL, Cairncross JG. Focus on central nervous system neoplasia. *Cancer Cell* 1 (2), 125-128(2002).
33. Louis DN, Cavenee WK. Molecular biology of central nervous system tumors. In: *Cancer: Principles and Practice of Oncology*. (DeVita VT Jr, Hellman S, Rosenberg SA, Eds), 7th Ed., Lippincott-Raven, Philadelphia, PA (2004).
34. Louis DN. Molecular pathology of malignant glioma. *Ann Rev Pathol Mech Dis* 1, 97-124(2006).
35. Stemmer-Rachamimov AO, Louis DN, Nielsen GP, et al. Comparative pathology of nerve sheath tumors in mouse models and humans. *Cancer Res* 64, 3718-3724(2004).
36. Zhu Y, Guignard F, Zhao D, et al. Early inactivation of p53 tumor suppressor gene cooperating with NF1 loss induces malignant astrocytoma. *Cancer Cell* 8,119-130(2005).

37. Galli R, Binda E, Orfanelli U, et al. Isolation and characterization of tumorigenic, stem-like neural precursors from human glioblastoma. *Cancer Res* 64,7011-7021(2004).
38. Singh SK, Hawkins C, Clarke ID, et al. Identification of human brain tumor initiating cells. *Nature* 432,396-401(2004).
39. Watanabe K, Tachibana O, Sata K, et al. Overexpression of the EGF receptor and p53 mutations are mutually exclusive in the evolution of primary and secondary glioblastoma. *Brain Pathol* 6,217-223(1996).
40. Ueki K, Ono Y, Henson JW, et al. CDKN2/p16 or RB alterations occur in the majority of glioblastoma and are inversely correlated. *Cancer Res* 56,150-153(1996).
41. Fujisawa H, Kurrer M, Reis RM, et al. Acquisition of the glioblastoma phenotype during astrocytoma progression is associated with loss of heterozygosity on 10q25-pter. *Am J Pathol* 155,387-394(1999).
42. Li J, Yen C, Liaw D, et al. PTEN, a putative protein tyrosine phosphatase gene mutated in human brain, breast and prostate cancer. *Science* 275, 1943-1947(1997).
43. Hermanson M, Funa K, Hartman M, et al. Platelet-derived growth factor and its receptors in human glioma tissue: expression of messenger RNA and protein suggests the presence of autocrine and paracrine loops. *Cancer Res* 52, 3213-3219(1992).
44. Rao JS. Molecular mechanisms of glioma invasiveness: The role of proteases. *Nat Rev Cancer* 3,489-501(2003).
45. Brat DJ, Mapstone TB. Malignant glioma physiology: cellular response to hypoxia and its role in tumor progression. *Ann Intern Med* 138,659-668(2003).

46. Brat DJ, Van Meir EG. Vaso-occlusive and prothrombotic mechanisms associated with tumor hypoxia, necrosis, and accelerated growth in glioblastoma. *Lab Invest* 84,397-405(2004).
47. Brat DJ, Castellano-Sanchez AA, Hunter SB, et al. Pseudopalisades in glioblastoma are hypoxic, express extracellular matrix proteases, and are formed by an actively migrating cell population. *Cancer Res* 64,920-927(2004).
48. Esteller M, Garcia-Foncillas J, Andion E, et al. Inactivation of the DNA-repair gene MGMT and the clinical response of gliomas to alkylating agents. *N Engl J Med* 343,1350-1354(2000).
49. Hegi ME, Diserens AC, Godard S, et al. Clinical trial substantiates the predictive value of O-6-methylguanine-DNA methyltransferase promoter methylation in glioblastoma patients treated with temozolomide. *Clin Cancer Res* 10,1841-1871(2004).
50. \*\*Hegi ME, Diserens AC, Gorlia T, et al. MGMT gene silencing and benefit from temozolomide in glioblastoma. *N Engl J Med* 352(10), 997-1003(2005).  
  
A sub-study of the EORTC TMZ GBM trial indicating the favorable benefit with respect to survival in patients with low content of the MGMT protein.
51. Chang SM, Parney IF, Huang W, et al. Patterns of care for adults with newly diagnosed malignant glioma. *JAMA* 293,557-564(2005).
52. Kondziolka D, Bernstein M, Resch L, et al. Significance of hemorrhage into brain tumors: Clinicopathological study. *J Neurosurg* 67,852-860(1987).
53. Yung WA, Horten BC, Shapiro WR. Meningeal gliomatosis: A review of 12 cases. *Ann Neurol* 8,605-609(1980).
54. Chamberlain MC. Combined-modality treatment of leptomeningeal gliomatosis. *Neurosurgery* 52,324-330(2003).

55. Bragg DG, Osborn AG. CNS imaging of neoplasms. *Int J Radiat Oncol Biol Phys* 21,841-860(1991).
56. Jaeckle KA. Neuroimaging for central nervous system tumors. *Semin Oncol* 18,150-158(1991).
57. Brem SS, Bierman PJ, Black P, Blumenthal DT, Brem H, et al. Central nervous system cancers: Clinical practice guidelines in oncology. *J Natl Compr Canc Netw* 3,644-690(2005).
58. \*\*Stupp R, Mason WP, van den Bent M, et al. Radiotherapy plus concomitant and adjuvant temozolomide for glioblastoma. *NEJM* 352,987-96(2005).  
A randomized trial by the EORTC defining a new standard of care for patients with newly diagnosed GBM.
59. \*\*Cairncross G, Berkey B, Shaw E, Jenkins R, Scheithauer B, et al. Phase III trial of chemotherapy plus radiotherapy compared with radiotherapy alone for pure and mixed anaplastic oligodendroglioma: Intergroup Radiation Oncology Group trial 9402. *J Clin Oncol* 24(18), 2707-2714(2006).  
A randomized trial of anaplastic oligodendrogliomas showing no benefit (except with respect to patients with codeleted tumors showing an improvement in PFS) to neoadjuvant PCV chemotherapy in either nondeleted or codeleted tumors.
60. \*\*van den Bent MJ, Carpentier AF, Brandes AA, Sanson M, Taphoorn MJB, et al. Adjuvant procarbazine, Lomustine and vincristine improves progression free survival but not overall survival in newly diagnosed anaplastic oligodendrogliomas and oligoastrocytomas: a randomized European Organization for Research and Treatment of Cancer Phase III trial. *J Clin Oncol* 24(18),2715-2722(2006).  
A randomized trial of anaplastic oligodendrogliomas showing no benefit to neoadjuvant PCV chemotherapy in either nondeleted or codeleted tumors i.e. regardless of genotype.

61. Jaeckle KA, Hess KR, Yung WK, et al. Phase II evaluation of temozolomide and 13-cis-retinoic acid for the treatment of recurrent and progressive malignant glioma: a North American Brain Tumor Consortium study. *J Clin Oncol* 21(12), 2305-2311(2003).
62. \*\*Vrendenburgh JJ, Desjardins A, Herndon JE 2nd, Dowell JM, Reardon DA, Quinn JA, et al. Phase II Trial of Bevacizumab and Irinotecan in Recurrent Malignant Glioma. *Clin Cancer Res* 13(4), 1253-1259(2007).  
A single institution study demonstrating efficacy of antiangiogenic therapy in the treatment of recurrent WHO Grade III malignant gliomas.
63. Batchelor TT, Sorensen AG, diTomaso E, Zhang WT, Duda DG, et al. AZD2171, a pan-VEGF receptor tyrosine kinase inhibitor, normalizes tumor vasculature and alleviates edema in glioblastoma patients. *Cancer Cell* 11, 83-95(2007).
64. Nabors LB, Mikkelsen T, Rosenfeld SS, Hochberg F, Akella NS, et al. Phase I and correlative biology study of cilengitide in patients with recurrent malignant glioma. *J Clin Oncol* 25(13), 1651-1662(2007).
65. Combs SE, Thilmann C, Edler L, Debus J, Schultz-Ertner D. Efficacy of fractionated stereotactic reirradiation in recurrent gliomas: long-term results in 172 patients treated in a single institution. *J Clin Oncol* 23 (34), 8863-8869(2005).
66. Ulm AJ, Friedman WA, Bradshaw P, Fote KD, Bova FJ. Radiosurgery in the management of malignant gliomas: the University of Florida experience. *Neurosurgery* 57,512-517(2005).
67. Muller W, Afra D, Schroder R. Supratentorial recurrences of gliomas: Morphological studies in relation to time intervals with astrocytomas. *Acta Neurochir (Wien)* 37, 75-84(1977).

68. Laws ER, Taylor WF, Clifton MB et al. Neurosurgical management of low-grade astrocytoma of the cerebral hemispheres. *J Neurosurg* 61,665-673(1984).
69. Piepmeier J, Christopher S, Spencer D, Byrne T, Kim J, Knisel JP, et al. Variations in the natural history and survival of patients with supratentorial low-grade astrocytomas. *Neurosurgery* 38,872-878(1996).
70. Schmidt MH, Berger MS, Lamborn KR, Aldape K, McDermott MW, et al. Repeated operations for infiltrative low-grade gliomas without intervening therapy. *J Neurosurg* 98(6),1165-1169(2003).
71. Brandes AA, Nicolardi L, Tosoni A, Gardiman M, Luzzolino P, et al. Survival following adjuvant PCV or temozolomide for anaplastic astrocytoma. *Neuro-Oncol* 8(3):253-260(2006).
72. Sathornsumetee S, Reardon D, Desjardins A, Quinn JA, Vredenburgh JJ, Rich JN. Molecularly targeted therapy for malignant glioma. *Cancer* 110,113-24(2007).

## TABLES

Table 1: Transformation of Low Grade Gliomas to Higher-Grade Gliomas

---

<u>Author [reference]</u>	<u>Low Grade Astrocytoma Rate of transformation</u>	<u>Oligodendroglioma Rate of transformation</u>
Muller [62]	89%	65%
Laws [63]	49%	Not stated
Piepmeir [64]	43%	Not stated
Schmidt [65]	50%	55%

Table 2: RTOG recursive partitioning analysis for anaplastic astrocytoma

Class	Age (years)	Mental status	Karnofsky performance status	Median overall survival (years)	2-year survival
1	<50	Normal	100	58.6	76%
2	>50	Normal	>70	37.2	68%
3	>50	Abnormal	>70	17.9	35%
4	>50	Normal	<70	11.1	15%

Table 3: Survival as a function of age: anaplastic astrocytoma

Age (years)	1-year survival	2-year survival	5-year survival	10-year survival
0-19	78.1%	61%	52.4%	47.8%
20-44	85.9	72.6	49.5	32.8
45-64	53.9	32.1	16.1	11.7
65+	20.4	6.0	2.4	1.7

Table 4: Adjuvant chemotherapy trials for anaplastic astrocytoma

Author [Reference]	#	Treatment comparison					Outcome (months)	
		RT	PCV	BCNU	TMZ	PCV+DFMO	Median progression free survival	Median overall survival
Levin [8]	72		+	+			15.7/31.5	20.5/39.3
Prados [2]	432		+	+				36/36
MRC [1]	124	+	+					13/15
Levin [19]	249		+			+	22.2/56.2	46/71.2
Prados [22]	40	+*	+					32/32
van den Bent [60]	233	+	+					24/24
Cairncross [59]	100	+	+^					33/33
Brandes [71]	109		+		+		36.1/34.4	48+/48+

Table 5: Anaplastic Glioma: Evidence-Based Management

- Maximum safe resection
- Post-operative radiotherapy
- No established role for chemotherapy
- No role for genotyping as a guide to management

Table 6: Anaplastic Astrocytoma: Proposed Randomized Adjuvant Clinical Trials

- RTOG 9813 (closed prematurely)
  - Comparison (tissue not required except for central review)
    - ❖ BCNU + RT followed by BCNU
    - ❖ TMZ (5/28) + RT followed by TMZ (5/28)
- EORTC (CATNON trial)
  - Intact 1p or 19q (tissue required)
  - 2x2 factorial design
  - Comparison
    - ❖ TMZ + RT
      - No post-RT TMZ
      - Post-RT TMZ
    - ❖ RT
      - No post-RT TMZ
      - Post-RT TMZ

Table 7: Chemotherapy treatment of recurrent anaplastic astrocytoma

Author	Trial	Number	Outcome		
			Response rate	6-month progression free survival	Median overall survival
Wong [11]	Composite of 8	150	14%	31%	47 weeks
Yung [14]	TMZ	162	35%	44%	54.4 weeks
Brem [24]	Gliadel	28	n/s	64%	31 weeks
Yung [26]	cRA	28	11%	n/s	34weeks
Jaekle[61]	cRA+TMZ	28	15%	46%	47 weeks
Levin [23]	DFMO	44	9%	n/s	62 weeks
Levin [25]	TPDC	38	34%	n/s	50 weeks
Chamberlain [27]	Placlitaxel	24	13%	n/s	72 weeks
Chamberlain [29]	Cyclophosphamide	40	22.5%	40%	28 weeks
Chamberlain [28]	CPT-11	40	23%	40%	28 weeks
Vrendenburgh [62]	CPT-11+bevacizumab	9	67%	56%	n/s

Legend:

TMZ            temozolomide

cRA            cis-retinoic acid

DFMO        enflornithine

TPDC        6-thioguanine, procarbazine, dibromodulcitol and CCNU

n/s            not state

## FIGURES

Figure 1. Molecular Ontogeny and Clinical Outcome in Patients with Astrocytomas

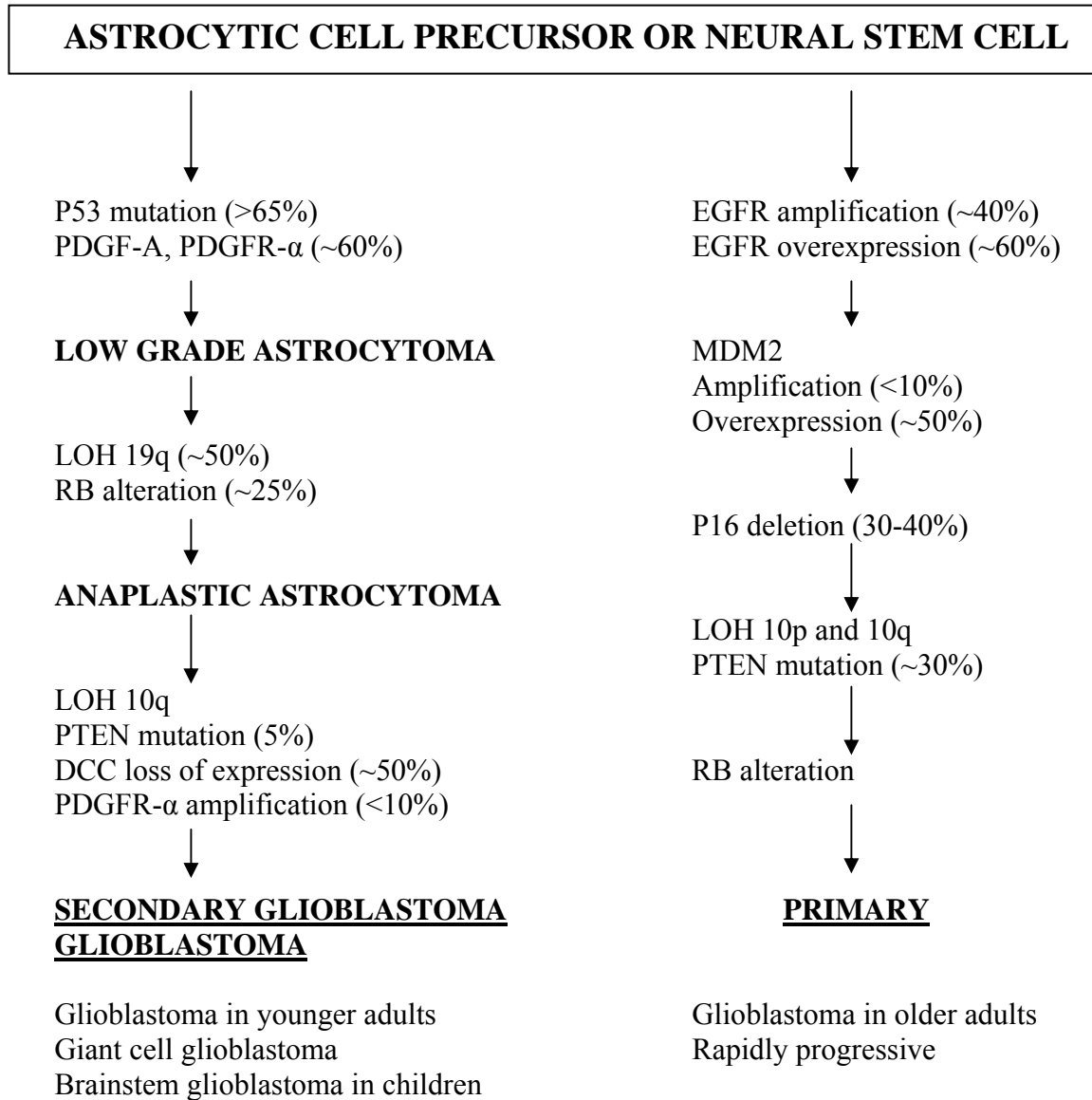


Figure 2: Molecular Gliomagenesis and Potential Targets of Therapy(used with permission; reference 72)

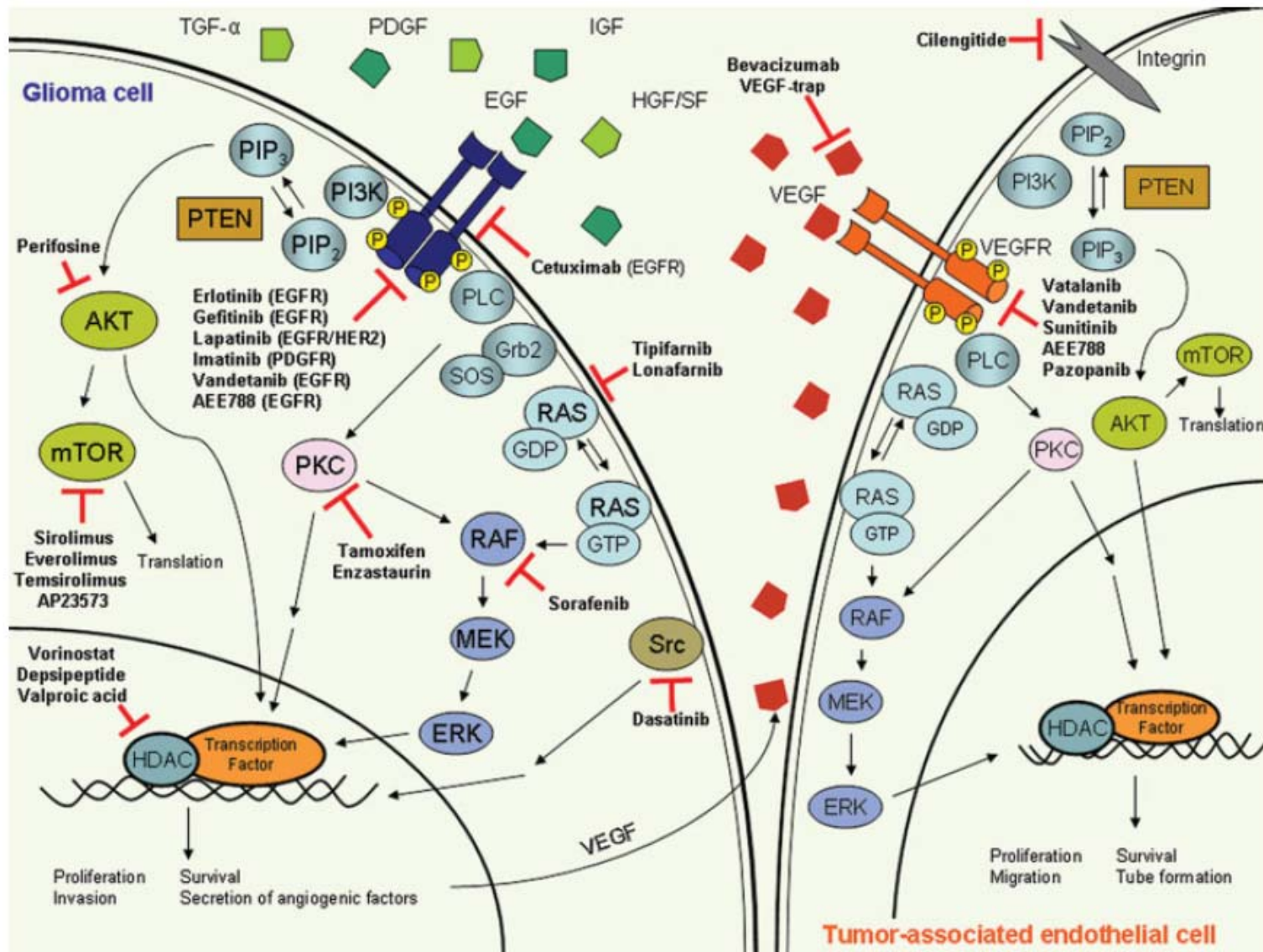


Figure 3: Etiology of Symptoms in Patients with Brain Tumors

Compression	Focal weakness, sensory loss, visual disturbance, aphasia
Irritation	Seizures
Increased ICP or ventricular obstruction	Headaches, altered level of consciousness, incontinence, ataxia, papilledema, herniation syndromes

Figure 4: Surgery: General Outcomes in Malignant Glioma

- Improved overall survival rates
- Improved results of subsequent radiation therapy and chemotherapy
- Improved clinical outcomes
- Decreased probability of further mutation toward resistance