

# NEOPLASTIC MENINGITIS

Marc C. Chamberlain, M.D.

Department of Neurology and Neurological Surgery

University of Southern California

Keck School of Medicine

Norris Comprehensive Cancer Center and Hospital

1441 Eastlake Avenue

Room 3459

Los Angeles, California 90033-0804

Phone: (323) 865-3945

Fax: (323) 685-0061

E-mail: [chamberl@usc.edu](mailto:chamberl@usc.edu)

## **Abstract**

Neoplastic meningitis (NM) is a common problem in neuro-oncology occurring in approximately 5% of all patients with cancer and is the third most common site of central nervous system (CNS) metastases. NM is a disease affecting the entire neuraxis and therefore clinical manifestations are pleomorphic affecting the spine, cranial nerves and cerebral hemispheres. Because of craniospinal disease involvement, staging and treatment need encompass all cerebrospinal fluid (CSF) compartments. Treatment of NM utilizes involved-field radiotherapy of bulky or symptomatic disease sites and intra-CSF drug therapy. The inclusion of concomitant systemic therapy may benefit patients with NM and may obviate the need for intra-CSF chemotherapy. At present, intra-CSF drug therapy is confined to three chemotherapeutic agents (i.e. methotrexate, cytosine arabinoside and thio-TEPA) administered by a variety of schedules either by intralumbar or intraventricular drug delivery. Although treatment of NM is palliative with an expected median patient survival of 2 to 6 months, it often affords stabilization and protection from further neurologic deterioration in patients with NM.

## **Epidemiology**

Neoplastic meningitis is diagnosed in 4 to 15% of patients with solid tumors (in which case it is termed carcinomatous meningitis), 5 to 15% of patients with leukemia and lymphoma (termed leukemic or lymphomatous meningitis respectively), and 1 to 2 % of patients with primary brain tumors<sup>1-5</sup>. Autopsy studies show that 19% of patients

with cancer and neurologic signs and symptoms have evidence of meningeal involvement<sup>6</sup>. Adenocarcinoma is the most frequent histology and breast, lung, and melanoma are the most common primary sites to metastasize to the leptomeninges (Table 1)<sup>3,7,8</sup>. Although small cell lung cancer and melanoma have the highest rates of spread to the leptomeninges (11% and 20% respectively<sup>9,10</sup>), because of the higher incidence of breast cancer (with a 5% rate of spread<sup>11</sup>), the latter accounts for most cases in large series of the disorder<sup>1,7</sup>.

NM usually presents in patients with widely disseminated and progressive systemic cancer (>70%) but it can present after a disease-free interval (20%) and even be the first manifestation of cancer (5-10%), occasionally in the absence of other evidence of systemic disease<sup>7,12-14</sup>

## **Pathogenesis**

Cancer cells reach the meninges by various routes: 1) hematogenous spread, either through the venous plexus of Batson or by arterial dissemination; 2) direct extension from contiguous tumor deposits; 3) and through centripetal migration from systemic tumors along perineural or perivascular spaces<sup>15,16 17</sup>.

Once cancer cells have entered the subarachnoid space, cancer cells are transported by CSF flow resulting in disseminated and multifocal neuraxis seeding of the leptomeninges. Tumor infiltration is most prominent in the base of brain (specifically the basilar cisterns) and dorsal surface of the spinal cord (in particular the cauda equina)<sup>5,18</sup>. Hydrocephalus or impairment of CSF flow may occur due to ependymal

nodules or tumor deposits obstructing CSF outflow, particularly at the level of the fourth ventricle, basal cisterns, cerebral convexity or spinal subarachnoid space.

### **Clinical Features**

Leptomeningeal carcinomatosis classically presents with pleomorphic clinical manifestations encompassing symptoms and signs in three domains of neurological function: 1) the cerebral hemispheres; 2) the cranial nerves; and 3) the spinal cord and associated roots. Signs on examination generally exceed patient reported symptoms.

The most common manifestations of cerebral hemisphere dysfunction are headache and mental status changes. Other signs include confusion, dementia, seizures and hemiparesis. Diplopia is the most common symptom of cranial nerve dysfunction with the VI cranial nerve being the most frequently affected, followed by cranial nerve III and IV. Trigeminal sensory or motor loss, cochlear dysfunction and optic neuropathy are also common findings. Spinal signs and symptoms include weakness (lower extremities more often than upper), dermatomal or segmental sensory loss and pain in the neck, back, or following radicular patterns. Nuchal rigidity is only present in 15% of cases<sup>3,7,8,13</sup>.

A high index of suspicion needs to be entertained in order to make the diagnosis of NM. The finding of multifocal neuraxis disease in a patient with known malignancy is strongly suggestive of NM, but it is also common for patients with NM to present with isolated syndromes such as symptoms of raised intracranial pressure, cauda equina syndrome or cranial neuropathy.

New neurological signs and symptoms may represent progression of NM but must be distinguished from the manifestations of parenchymal disease (30-40% of patients with NM will have co-existent parenchymal brain metastases), from side effects of chemotherapy or radiation used for treatment and rarely from paraneoplastic syndromes. At presentation, NM must also be differentiated from chronic meningitis due to tuberculosis, fungal infection or sarcoidosis as well as from metabolic and toxic encephalopathies in the appropriate clinical setting <sup>7,20</sup>.

## **Diagnosis**

### CSF examination

The most useful laboratory test in the diagnosis of NM is the CSF exam. Abnormalities include increased opening pressure (>200 mm of H<sub>2</sub>O), increased leukocytes (>4/mm<sup>3</sup>), elevated protein (>50mg/dl) or decreased glucose (<60mg/dl), which though suggestive of NM are not diagnostic. The presence of malignant cells in the CSF is diagnostic of NM but in general, as is true for most cytological analysis, assignment to a particular tumor is not possible <sup>21</sup>.

In patients with positive CSF cytology (see below), up to 45% will be cytologically negative on initial examination <sup>6</sup>. The yield is increased to 80% with a second CSF examination but little benefit is obtained from repeat lumbar punctures after two lumbar punctures <sup>7</sup>. Of note, a series including lymphomatous and leukemic meningitis by Kaplan et al <sup>3</sup> observed the frequent dissociation between CSF cell count and malignant cytology (29% of cytologically positive CSF had concurrent CSF counts of less than 4/mm<sup>3</sup>). Murray et al <sup>22</sup> showed that CSF levels of protein, glucose and malignant cells<sup>23</sup>

vary at different levels of the neuraxis even if there is no obstruction of the CSF flow. This finding reflects the multifocal nature of neoplastic meningitis and explains that CSF obtained from a site distant to that of the pathologically involved meninges may yield a negative cytology.

Of the 90 patients reported by Wasserstrom et al<sup>7</sup>, 5% had positive CSF cytology only from either the ventricles or cisterna magna. In a series of 60 patients with NM, positive lumbar CSF cytology at diagnosis and no evidence of CSF flow obstruction, ventricular and lumbar cytologies obtained simultaneously were discordant in 30% of cases<sup>24</sup>. The authors observed that in the presence of spinal signs or symptoms, the lumbar CSF was more likely to be positive and, conversely, in the presence of cranial signs or symptoms, the ventricular CSF was more likely to be positive. Not obtaining CSF from a site of symptomatic or radiographically demonstrated disease was found to correlate with false negative cytology results in a prospective evaluation of 39 patients, as did withdrawing small CSF volumes (<10.5ml), delayed processing of specimens and obtaining less than two samples<sup>25</sup>. Even after correcting for these factors there is remains a substantial group of patients with NM and persistently negative CSF cytology. Glass reported on a postmortem evaluation evaluating the value of premortem CSF cytology<sup>6</sup>. Glass demonstrated that up to 40% of patients with clinically suspected NM proven at time of autopsy are cytologically negative. This figure increased to >50% in patients with focal NM.

The low sensitivity of CSF cytology makes it difficult not only to diagnose NM, but also to assess the response to treatment. Biochemical markers, immunohistochemistry

and molecular biology techniques applied to CSF have been explored in an attempt to find a reliable biological marker of disease.

Numerous biochemical markers have been evaluated but in general, their use has been limited by poor sensitivity and specificity. Particular tumor markers such as CEA (carcinoembryogenic antigen) from adenocarcinomas, and AFP ( $\alpha$ -fetoprotein) and  $\beta$ -HCG ( $\beta$ -human chorionic gonadotropin) from testicular cancers and primary extragonadal CNS tumors can be relatively specific for NM when elevated in CSF in the absence of markedly elevated serum levels<sup>16,26</sup>. Nonspecific tumor markers such as CK-BB (creatine-kinase BB isoenzyme), TPA (tissue polypeptide antigen,  $\beta_2$ microglobulin,  $\beta$ -glucuronidase, LDH isoenzyme-5 and more recently VEGF (vascular endothelial growth factor) can be strong indirect indicators of NM but none are sensitive enough to improve the cytological diagnosis<sup>27 28-32</sup>. The use of these biochemical markers can be helpful as adjunctive diagnostic tests and, when followed serially, to assess response to treatment. Occasionally, in patients with clinically suspected NM and negative CSF cytology, they may support the diagnosis of NM<sup>33</sup>.

Use of monoclonal antibodies for immunohistochemical analysis in NM does not significantly increase the sensitivity of cytology alone<sup>34-36</sup>. However, in the case of leukemia and lymphoma, antibodies against surface markers can be used to distinguish between reactive and neoplastic lymphocytes in the CSF<sup>37</sup>.

Cytogenetic studies have also been evaluated in an attempt to improve the diagnostic accuracy of NM. Flow cytometry and DNA single cell cytometry, techniques that measure the chromosomal content of cells, and fluorescent *in situ* hybridization (FISH), that detects numerical and structural genetic aberrations as a sign of

malignancy, can give additional diagnostic information, but still have a low sensitivity<sup>38-</sup>  
<sup>40</sup>. Polymerase-chain reaction (PCR) can establish a correct diagnosis when cytology is inconclusive, but the genetic alteration of the neoplasia must be known for it to be amplified with this technique, and this is generally not the case, particularly in solid tumors<sup>41</sup>.

In cases where there is no evidence of systemic cancer and CSF exams remain inconclusive, a meningeal biopsy may be diagnostic. The yield of this test increases if the biopsy is taken from an enhancing region on MRI (see below) and if posterior fossa or pterional approaches are used<sup>42</sup>.

#### Neuroradiographic studies

Magnetic resonance imaging with gadolinium enhancement (MR-Gd) is the technique of choice to evaluate patients with suspected leptomeningeal metastasis<sup>43</sup>. Because NM involves the entire neuraxis, imaging of the entire CNS is required in patients considered for further treatment. T1-weighted sequences, with and without contrast, combined with fat suppression T2-weighted sequences constitute the standard examination<sup>44</sup>. MRI has been shown to have a higher sensitivity than cranial contrast enhanced computed tomography (CE-CT) in several series<sup>43,45</sup>, and is similar to computerized tomographic myelography (CT-M) for the evaluation of the spine, but significantly better tolerated<sup>46,47</sup>.

Any irritation of the leptomeninges (i.e. blood, infection, cancer) will result in their enhancement on MRI, which is seen as a fine signal-intense layer that follows the gyri and superficial sulci. Subependymal involvement of the ventricles often results in ventricular enhancement. Some changes such as cranial nerve enhancement on

cranial imaging and intradural extramedullary enhancing nodules on spinal MR (most frequently seen in the cauda equina) can be considered diagnostic of NM in patients with cancer<sup>48</sup>. Lumbar puncture itself can rarely cause a meningeal reaction leading to dural-arachnoidal enhancement so imaging should be obtained preferably prior to the procedure<sup>49</sup>. MR-Gd still has a 30% incidence of false negative results so that a normal study does not exclude the diagnosis of NM. On the other hand, in cases with a typical clinical presentation, abnormal MR-Gd alone is adequate to establish the diagnosis of NM<sup>33,48</sup>.

Radionuclide studies using either <sup>111</sup>Indium-diethylenetriamine pentaacetic acid or <sup>99</sup>Tc macro-aggregated albumin, constitute the technique of choice to evaluate CSF flow dynamics<sup>17,50</sup>. Abnormal CSF circulation has been demonstrated in 30 to 70% of patients with NM, with blocks commonly occurring at the skull base, the spinal canal and over the cerebral convexities<sup>47,50,51</sup>. Patients with interruption of CSF flow demonstrated by radionuclide ventriculography have been shown in three clinical series to have decreased survival when compared to those with normal CSF flow<sup>50,52,53</sup>. Involved field radiotherapy to the site of CSF flow obstruction, restores flow in 30% of patients with spinal disease and 50% of patients with intracranial disease<sup>54</sup>. Re-establishment of CSF flow with involved-field radiotherapy followed by intrathecal chemotherapy led to longer survival, lower rates of treatment related morbidity and lower rate of death from progressive NM, compared to the group that had persistent CSF blocks<sup>50,52</sup>. These findings may reflect that CSF flow abnormalities prevent homogenous distribution of intrathecal chemotherapy, resulting in 1) protected sites where tumor can progress and 2) in accumulation of drug at other sites leading to

neurotoxicity and systemic toxicity. Based on this, many authors recommend that intrathecal chemotherapy be preceded by a radionuclide flow study and if a block is found, that radiotherapy be administered in an attempt to re-establish normal flow <sup>16,55</sup>.

### **Staging**

In summary, patients with suspected NM should undergo one or two lumbar punctures, cranial MR-Gd, spinal MR-Gd and a radioisotope CSF flow study to rule out sites of CSF block. If cytology remains negative and radiological studies are not definitive, consideration may be given to ventricular or lateral cervical CSF analysis based on suspected site of predominant disease. If the clinical scenario or radiological studies are highly suggestive of NM, treatment is warranted despite persistently negative CSF cytologies.

### **Prognosis**

The median survival of untreated patients with NM is four to six weeks and death generally occurs due to progressive neurological dysfunction <sup>7</sup>. Treatment is intended to improve or stabilize the neurological status and to prolong survival. Fixed neurological defects are rarely improved with treatment <sup>16</sup> but progression of neurological deterioration may be halted in some patients and median survival can be increased to 4-6 months. Of the solid tumors (Table 2), breast cancer responds best, with median survivals of 6 months and 11 to 25% one-year survivals <sup>20,26,56</sup>. Numerous prognostic factors for survival and response have been looked at (age, gender, duration of signs of NM, increased protein or low glucose in CSF, ratio of lumbar/ventricular CEA, etc), but many remain controversial <sup>56</sup>. It is commonly accepted however, that patients will do poorly with intensive treatment of NM if they have poor performance status, multiple

fixed neurologic deficits, bulky CNS disease, co-existent carcinomatous encephalopathy and CSF flow abnormalities demonstrated by radionuclide ventriculography. In general patients with widely metastatic aggressive cancers that do not respond well to systemic chemotherapies, are also less likely to benefit from intensive therapy<sup>16,50, 57, 83</sup>. What appears clear is that, optimally, NM should be diagnosed in the early stages of disease to prevent progression of disabling neurological deficits, analogous to the clinical situation of epidural spinal cord compression.

## **Treatment**

The evaluation of treatment of NM is complicated by the lack of standard treatments, the difficulty of determining response to treatment given the sub-optimal sensitivity of the diagnostic procedures and that most patients will die of systemic disease, and the fact that most studies are small, non-randomized and retrospective<sup>56</sup>. However, it is clear that treatment of NM can provide effective palliation and in some cases result in prolonged survival. Treatment requires the combination of surgery, radiation and chemotherapy in most cases. Figure 1 outlines a treatment algorithm for NM.

### Surgery

Surgery is used in the treatment of NM for the placement of 1) intraventricular catheter and subgaleal reservoir for administration of cytotoxic drugs and 2) ventriculoperitoneal shunt in patients with symptomatic hydrocephalus.

Drugs can be instilled into the subarachnoid space by lumbar puncture or via an intraventricular reservoir system. The latter is the preferred approach because it is simpler, more comfortable for the patient and safer than repeated lumbar punctures. It

also results in a more uniform distribution of the drug in the CSF space and produces the most consistent CSF levels. In up to 10% of lumbar punctures drug is delivered to the epidural space, even if there is CSF return after placement of the needle, and drug distribution has been shown to be better after drug delivery through a reservoir<sup>58</sup>.

There are two basic types of reservoirs: the *Rickham style reservoir*, a flat rigid reservoir placed over a burr hole, and the *Ommaya reservoir*, a dome-shaped reservoir that can be palpated easily. They are generally placed over the right (non-dominant) frontal region using a small C-shaped incision. The catheter is placed in the frontal horn of the lateral ventricle or close to the foramen of Monroe through a standard ventricular puncture. In most cases anatomical landmarks suffice but ultrasonographic or CT guidance can be helpful in some situations<sup>59</sup>. It is very important to be sure that the tip and the side perforations of the catheter be inserted completely into the ventricle to avoid drug instillation into the brain parenchyma. Correct placement of the catheter should be checked by non-contrast CT prior to its use for drug administration and frequently it will show a small amount of air in both frontal horns<sup>60</sup>.

NM often causes communicating hydrocephalus leading to symptoms of raised intracranial pressure. Relief of sites of CSF flow obstruction with involved-field radiation should be attempted to avoid the need for CSF shunting. If hydrocephalus persists, a ventriculoperitoneal shunt should be placed to relieve the pressure because relief of pressure often results in clinical improvement. If possible an in-line on/off valve and reservoir should be used to permit the administration of intra-CSF chemotherapy, although some patients cannot tolerate having the shunt turned off to allow the circulation of the drug<sup>17</sup>.

Additionally, in patients with a persistent blockage of ventricular CSF, a lumbar catheter and reservoir can be used in addition to a ventricular catheter, to allow treatment of the spine with intrathecal chemotherapy, although as discussed earlier, patients with persistent CSF flow blocks after radiation are probably best managed by supportive care alone.

Finally, occasional patients may undergo a meningeal biopsy so as to pathologically confirm neoplastic meningitis. However in that most patients demonstrate MR leptomeningeal abnormalities, an abnormal CSF profile or a clinical examination consistent with NM, meningeal biopsies are rarely performed.

### Radiotherapy

Radiotherapy is used in the treatment of NM for a) palliation of symptoms, such as a cauda equina syndrome, b) to decrease bulky disease such as co-existent parenchymal brain metastases, and c) to correct CSF flow abnormalities demonstrated by radionuclide ventriculography. Patients may have significant symptoms without radiographic evidence of bulky disease and still benefit from radiation. For example, patients with low back pain and leg weakness should be considered for radiation to the cauda equina, and those with cranial neuropathies should be offered whole-brain or base of skull radiotherapy<sup>26</sup>.

Radiotherapy of bulky disease is indicated as intra-CSF chemotherapy is limited by diffusion to 2 to 3 mm penetration into tumor nodules. In addition, involved-field radiation can correct CSF flow abnormalities and this has been shown to improve patient outcome as discussed above. Whole neuraxis radiation is rarely indicated in the treatment of NM from solid tumors because it is associated with significant systemic

toxicity (severe myelosuppression and mucositis among other complications) and is not curative.

### Chemotherapy

Chemotherapy is the only treatment modality that can treat the entire neuraxis. Chemotherapy may be administered systemically or intrathecally.

Intrathecal chemotherapy is the mainstay of treatment for NM. Retrospective analysis or comparison to historical series suggest that the administration of chemotherapy to the CSF improves the outcome of patients with NM <sup>1,20,52,61,62</sup>. However, it is noted that most series will exclude patients that are too sick to receive any treatment, which may be up to one third of patients with NM <sup>63</sup>. Three agents are routinely used: methotrexate, cytarabine (including liposomal cytarabine or DepoCyt<sup>®</sup>) and thio-TEPA. No difference in response has been seen when comparing single agent methotrexate with thio-TEPA <sup>16</sup> or when using multiple agent (methotrexate, thio-TEPA and cytarabine or methotrexate and cytarabine) versus single agent methotrexate in adult randomized studies of NM <sup>64-66</sup>. Table 3 outlines the common treatment regimens for these drugs. A sustained-release liposomal form of cytarabine (DepoCyt<sup>®</sup>) results in cytotoxic cytarabine levels in the CSF for  $\geq 10$  days and when given bimonthly and compared to biweekly methotrexate, resulted in longer time to neurological progression in patients with NM due to solid tumors <sup>67</sup>. Furthermore, quality of life and cause of death favored DepoCyt<sup>®</sup> over methotrexate. These findings were confirmed in a study of lymphomatous meningitis and in an open label study suggesting that DepoCyt<sup>®</sup> should be considered the drug of first choice in the treatment of NM when experimental therapies are unavailable <sup>82,85</sup>.

Complications of intrathecal chemotherapy include those related to the ventricular reservoir and those related to the chemotherapy administered. The most frequent complications of ventricular reservoir placement are malposition (rates reported between 3 and 12%), obstruction and infection (usually skin flora). CSF infection occurs in 2 to 13% of patients receiving intrathecal chemotherapy. It commonly presents with headache, changes in neurologic status, fever and malfunction of the reservoir. CSF pleocytosis is commonly encountered. The most frequently isolated organism is *Staphylococcus epidermidis*. Treatment requires intravenous with or without oral and intra-ventricular antibiotics. Some authors advocate the routine removal of the ventricular reservoir, whilst others reserve device removal for those that do not clear with antibiotic therapy. Routine culture of CSF is not recommended because of the high rate of contamination with skin flora in the absence of infection <sup>1,5,51,60,68</sup>.

Myelosuppression can occur after administration of intrathecal chemotherapies and it is recommended that folinic acid rescue (10mg every 6 hours for 24 hours) be given orally after the administration of methotrexate to mitigate this complication. Chemical aseptic meningitis occurs in nearly half of patients treated by intraventricular administration and is manifested by fever, headache, nausea, vomiting, meningismus and photophobia. In the majority of patients this inflammatory reaction can be treated in the outpatient setting with oral antipyretics, antiemetics and corticosteroids. Rarely treatment-related neurotoxicity occurs and may result in a symptomatic subacute leukoencephalopathy or myelopathy. However in patients with NM and prolonged survival, the combination of radiotherapy and chemotherapy frequently results in a late leukoencephalopathy evident on neuroradiographic studies and is occasionally symptomatic <sup>1,5,69</sup>.

The rationale to give intrathecal chemotherapy is based on the presumption that most chemotherapeutic agents when given systemically have poor CSF penetration and do not reach therapeutic levels. Exceptions to this would be systemic high-dose methotrexate, cytarabine and thio-TEPA, all of which result in cytotoxic CSF levels. Their systemic administration however, is limited by systemic toxicity and the difficulty to integrate these regimens into other chemotherapeutic programs being used to manage systemic disease. Some authors argue that intrathecal chemotherapy does not add to improved outcome in the treatment of NM, since systemic therapy can obtain access to the subarachnoid deposits through their own vascular supply <sup>63</sup>. In a retrospective comparison of patients treated with systemic chemotherapy and radiation to involved areas, plus or minus intrathecal chemotherapy, Bokstein et al <sup>70</sup> did not find significant differences in response rates, median survival or proportion of long term survivors amongst the two groups but, of course, the group that did not receive the intrathecal treatment was spared the complications of this modality. Glantz et al <sup>71</sup> treated 16 patients with high dose intravenous methotrexate and compared their outcome with a reference group of 15 patients treated with intrathecal methotrexate. They found response rates and survival were significantly better in the group treated with intravenous therapy. Finally, a recent report describes two patients with breast cancer in whom LM was controlled with systemic hormonal treatment <sup>72</sup>.

Nonetheless, intrathecal chemotherapy remains the preferred treatment route for NM at this time. New drugs are being explored to try to improve the efficacy, these include mafosphamide, diaziquone, topotecan <sup>73</sup>, gemcitabine, interferon- $\alpha$  and temozolomide <sup>74</sup> are some of the new drugs being evaluated for intrathecal

administration. Immunotherapy, using IL-2 and IFN- $\alpha$ <sup>75</sup>, <sup>131</sup>I-radiolabelled monoclonal antibodies<sup>76</sup> and gene therapy<sup>77</sup> are other modalities that are being explored in clinical trials.

### Supportive care

Not all patients with NM are candidates for the aggressive treatment outlined above. Most authors agree that combined-modality therapy should be offered to patients with life expectancy greater than 3 months and a Karnofsky performance status of greater than 60%.

Supportive care that should be offered to every patient, regardless of whether they receive NM directed therapy, include anticonvulsants for seizure control (seen in 10-15% of patients with NM), adequate analgesia with opioid drugs as needed as well as antidepressants and anxiolytics if necessary. Corticosteroids have a limited use in NM-related neurological symptoms, but can be useful to treat vasogenic edema associated with intraparenchymal or epidural metastases, or for the symptomatic treatment of nausea and vomiting together with routine antiemetics. Decreased attention and somnolence secondary to whole brain radiation can be treated with psychostimulants<sup>5</sup>.

## **CONCLUSIONS**

NM is a complicated disease for a variety of reasons. Firstly, most reports concerning NM treat all subtypes as equivalent with respect to CNS staging, treatment and outcome. However, clinical trials in oncology are based on specific tumor histology. Comparing responses in patients with carcinomatous meningitis due to breast cancer to patients with non-small cell lung cancer outside of investigational new drug trials may be

misleading. A general consensus is that breast cancer is inherently more chemosensitive than non-small cell lung cancer or melanoma and therefore survival following chemotherapy is likely to be different. This observation has been substantiated in patients with systemic metastases though comparable data regarding CNS metastases, and in particular NM is meager.

A second feature of NM, which complicates therapy, is deciding whom to treat. Not all patients necessarily warrant aggressive CNS-directed therapy, however, few guidelines exist permitting appropriate choice of therapy. Based on the prognostic variables determined clinically and by evaluation of extent of disease, a sizable minority of patients will not be candidates for aggressive NM-directed therapy. Therefore supportive comfort care (radiotherapy to symptomatic disease, antiemetics, and narcotics) is reasonably offered to patients with NM considered poor candidates for aggressive therapy as seen in Figure 1.

Thirdly, optimal treatment of NM remains poorly defined. Given these constraints, the treatment of NM today is palliative and rarely curative with a median patient survival of 2-3 months based on data of the four prospective randomized trials in this disease. However, palliative therapy of NM often affords the patient protection from further neurological deterioration and consequently an improved neurologic quality of life. No studies to date have attempted an economic assessment of the treatment of NM and therefore no information is available regarding a cost-benefit analysis as has been performed for other cancer directed therapies.

Finally, in patients with NM, the response to treatment is primarily a function of CSF cytology and secondarily of clinical improvement of neurologic signs and

symptoms. Aside from CSF cytology and perhaps biochemical markers, no other CSF parameters predict response. Furthermore, because CSF cytology may manifest a rostra-caudal disassociation, consecutive negative cytologist (defined as a complete response to treatment) requires confirmation by both ventricular and lumbar CSF cytologies. In general, only pain related neurologic symptoms improve with treatment. Neurologic signs such as confusion, cranial nerve deficit(s), ataxia and segmental weakness minimally improve or stabilize with successful treatment.

## References

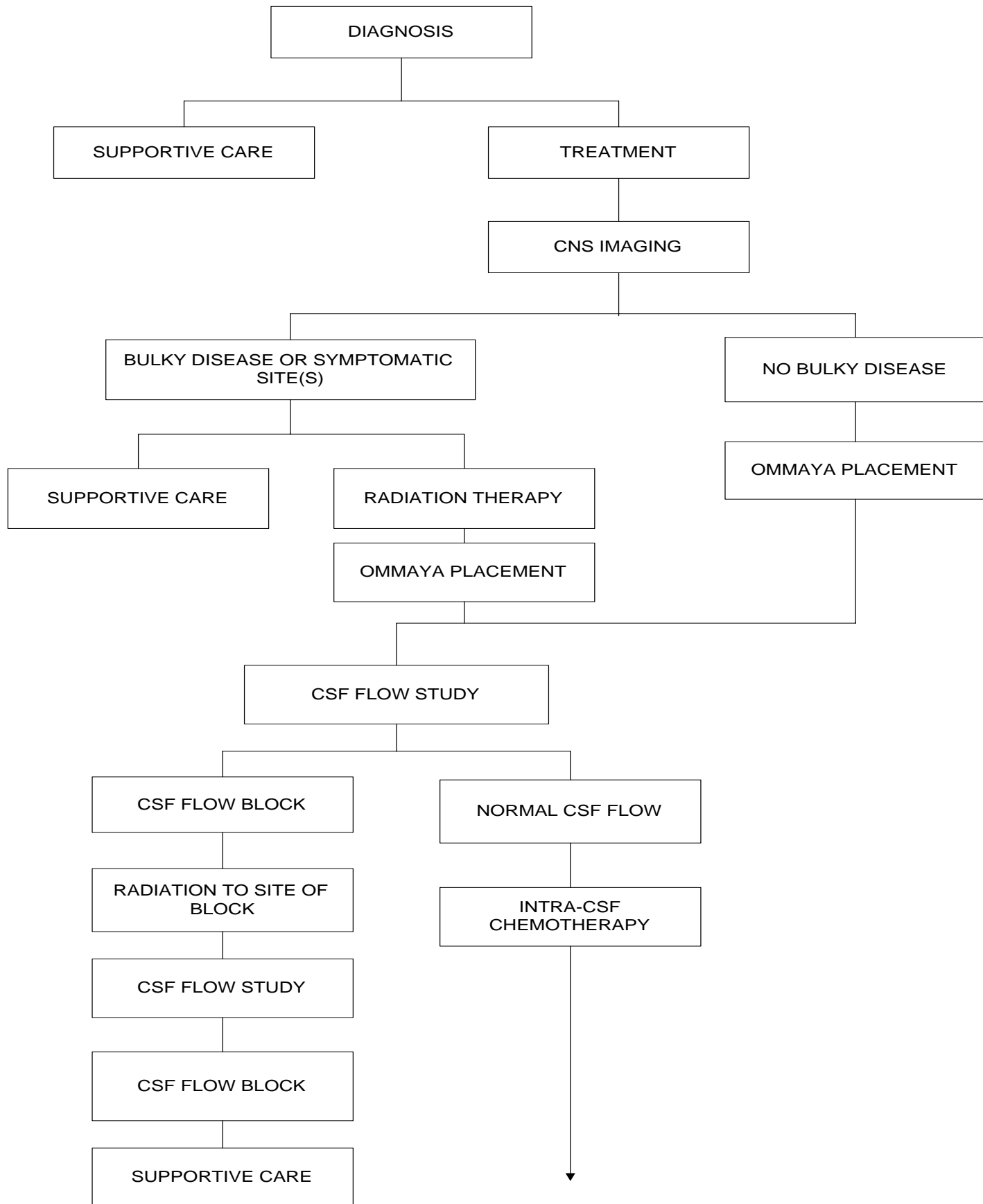1. Shapiro WR, Posner JB, Ushio Y et al. Treatment of meningeal neoplasms. *Cancer Treat Rep*; 61(4): 733-743, 1977.
2. Nugent JL, Bunn PA, Jr., Matthews MJ et al. CNS metastases in small cell bronchogenic carcinoma: increasing frequency and changing pattern with lengthening survival. *Cancer*, 44(5): 1885-1893, 1979.
3. Kaplan JG, DeSouza TG, Farkash A et al. Leptomeningeal metastases: comparison of clinical features and laboratory data of solid tumors, lymphomas and leukemia's. *J Neuro Oncol*; 9(3): 225-229, 1990.
4. Siegal T, Lossos A, Pfeffer MR. Leptomeningeal metastases: analysis of 31 patients with sustained off- therapy response following combined-modality therapy. *Neurology*; 44(8): 1463-1469, 1994.
5. Chamberlain MC. Carcinomatous meningitis. *Arch Neurol*; 54(1): 16-17, 1997.
6. Glass JP, Melamed M, Chernik NL et al. Malignant cells in cerebrospinal fluid (CSF): the meaning of a positive CSF cytology. *Neurology*; 29(10): 1369-1375, 1979.
7. Wasserstrom WR, Glass JP, Posner JB. Diagnosis and treatment of leptomeningeal metastases from solid tumors: experience with 90 patients. *Cancer*; 49(4): 759-772, 1982.
8. Little JR, Dale AJ, Okazaki H. Meningeal carcinomatosis. Clinical manifestations. *Arch Neurol*; 30(2): 138-143, 1974.
9. Rosen ST, Aisner J, Makuch RW et al. Carcinomatous leptomeningitis in small cell lung cancer: a clinicopathologic review of the National Cancer Institute experience. *Medicine (Baltimore)*; 61(1): 45-53, 1982.
10. Amer MH, Al Sarraf M, Baker LH et al. Malignant melanoma and central nervous system metastases: incidence, diagnosis, treatment and survival. *Cancer*; 42(2): 660-668, 1978.
11. Yap HY, Yap BS, Tashima CK et al. Meningeal carcinomatosis in breast cancer. *Cancer*; 42(1): 283-286, 1978.
12. van Oostenbrugge RJ, Twijnstra A. Presenting features and value of diagnostic procedures in leptomeningeal metastases. *Neurology*; 53(2): 382-385, 1999.
13. Balm M, Hammack J. Leptomeningeal carcinomatosis. Presenting features and prognostic factors. *Arch Neurol*; 53(7): 626-632, 1996.
14. Sorensen SC, Eagan RT, Scott M. Meningeal carcinomatosis in patients with primary breast or lung cancer. *Mayo Clin Proc*; 59(2): 91-94, 1984.
15. Gonzalez-Vitale JC, Garcia-Bunuel R. Meningeal carcinomatosis. *Cancer*; 37(6): 2906-2911, 1976.
16. Grossman SA, Krabak MJ. Leptomeningeal carcinomatosis. *Cancer Treat Rev*; 25(2): 103-119, 1999.
17. Chamberlain MC. Radioisotope CSF flow studies in leptomeningeal metastases. *J Neuro Oncol*; 38(2-3): 135-140, 1998.

18. Boyle R, Thomas M, Adams JH. Diffuse involvement of the leptomeninges by tumour--a clinical and pathological study of 63 cases. *Postgrad Med J*; 56(653): 149-158, 1980.
19. Wolfgang G, Marcus D, Ulrike S. Leptomeningeal Carcinomatosis; Clinical syndrome in different primaries. *Journal of Neuro-Oncology*; 38:103-110, 1998.
20. Chamberlain MC, Kormanik PR. Carcinomatous meningitis secondary to breast cancer: predictors of response to combined modality therapy. *J Neuro Oncol*; 35(1): 55-64, 1997.
21. Kolmel HW. Cytology of neoplastic meningitis. *J Neuro Oncol*; 38(2-3): 121-125, 1998.
22. Murray JJ, Greco FA, Wolff SN et al. Neoplastic meningitis. Marked variations of cerebrospinal fluid composition in the absence of extradural block. *Am J Med* 75(2): 289-294, 1983.
23. Rogers LR, Duchesneau PM, Nunez C et al. Comparison of cisternal and lumbar CSF examination in leptomeningeal metastasis. *Neurology* 42(6): 1239-1241, 1992.
24. Chamberlain MC, Kormanik PA, Glantz MJ. A comparison between ventricular and lumbar cerebrospinal fluid cytology in adult patients with leptomeningeal metastases. *Neuro-Oncol* 3(1): 42-45, 2001.
25. Glantz MJ, Cole BF, Glantz LK et al. Cerebrospinal fluid cytology in patients with cancer: minimizing false- negative results. *Cancer* 82(4): 733-739, 1998.
26. DeAngelis LM. Current diagnosis and treatment of leptomeningeal metastasis. *J Neuro Oncol* 38(2-3): 245-252, 1998.
27. Wasserstrom WR, Schwartz MK, Fleisher M et al. Cerebrospinal fluid biochemical markers in central nervous system tumors: a review. *Ann Clin Lab Sci*; 11(3): 239-251, 1981.
28. van Zanten AP, Twijnstra A, Hart AA et al. Cerebrospinal fluid lactate dehydrogenase activities in patients with central nervous system metastases. *Clin Chim Acta*; 161(3): 259-268, 1986.
29. Klee GG, Tallman RD, Goellner JR et al. Elevation of carcinoembryonic antigen in cerebrospinal fluid among patients with meningeal carcinomatosis. *Mayo Clin Proc*; 61(1): 9-13, 1986.
30. Twijnstra A, van Zanten AP, Hart AA et al. Serial lumbar and ventricle cerebrospinal fluid lactate dehydrogenase activities in patients with leptomeningeal metastases from solid and haematological tumours. *J Neurol Neurosurg Psychiatry*; 50(3): 313-320, 1987.
31. Twijnstra A, Ongerboer d, V, van Zanten AP et al. Serial lumbar and ventricular cerebrospinal fluid biochemical marker measurements in patients with leptomeningeal metastases from solid and hematological tumors. *J Neuro Oncol*; 7(1): 57-63, 1989.
32. Stockhammer G, Poewe W, Burgstaller S et al. Vascular endothelial growth factor in CSF: a biological marker for carcinomatous meningitis. *Neurology*; 54(8): 1670-1676, 2000.
33. Chamberlain MC. Cytologically negative carcinomatous meningitis: usefulness of CSF biochemical markers. *Neurology*; 50(4): 1173-1175, 1998.
34. Garson JA, Coakham HB, Kemshead JT et al. The role of monoclonal antibodies in brain tumour diagnosis and cerebrospinal fluid (CSF) cytology. *J Neuro Oncol*; 3(2): 165-171, 1985.
35. Hovestadt A, Henzen-Logmans SC, Vecht CJ. Immunohistochemical analysis of the cerebrospinal fluid for carcinomatous and lymphomatous leptomeningitis. *Br J Cancer*; 62(4): 653-654, 1990.

36. Boogerd W, Vroom TM, van Heerde P et al. CSF cytology versus immunocytochemistry in meningeal carcinomatosis. *J Neurol Neurosurg Psychiatry*; 51(1): 142-145, 1988.
37. van Oostenbrugge RJ, Hopman AH, Ramaekers FC et al. In situ hybridization: a possible diagnostic aid in leptomeningeal metastasis. *J Neuro Oncol*; 38(2-3): 127-133, 1998.
38. Cibas ES, Malkin MG, Posner JB et al. Detection of DNA abnormalities by flow cytometry in cells from cerebrospinal fluid. *Am J Clin Pathol* 88(5): 570-577, 1987.
39. Biesterfeld S, Bernhard B, Bamborschke S et al. DNA single cell cytometry in lymphocytic pleocytosis of the cerebrospinal fluid. *Acta Neuropathol (Berl)* 86(5): 428-432, 1993.
40. van Oostenbrugge RJ, Hopman AH, Arends JW et al. The value of interphase cytogenetics in cytology for the diagnosis of leptomeningeal metastases. *Neurology*; 51(3): 906-908, 1998.
41. Rhodes CH, Glantz MJ, Glantz L et al. A comparison of polymerase chain reaction examination of cerebrospinal fluid and conventional cytology in the diagnosis of lymphomatous meningitis. *Cancer*; 77(3): 543-548, 1996.
42. Cheng TM, O'Neill BP, Scheithauer BW et al. Chronic meningitis: the role of meningeal or cortical biopsy. *Neurosurgery*; 34(4): 590-595, 1994.
43. Chamberlain MC, Sandy AD, Press GA. Leptomeningeal metastasis: a comparison of gadolinium-enhanced MR and contrast-enhanced CT of the brain. *Neurology*; 40(3 Pt 1): 435-438, 1990.
44. Schumacher M, Orszagh M. Imaging techniques in neoplastic meningiosis. *J Neuro Oncol*; 38(2-3): 111-120, 1998.
45. Sze G, Soletsky S, Bronen R et al. MR imaging of the cranial meninges with emphasis on contrast enhancement and meningeal carcinomatosis. *AJR Am J Roentgenol*; 153(5): 1039-1049, 1989.
46. Schuknecht B, Huber P, Buller B et al. Spinal leptomeningeal neoplastic disease. Evaluation by MR, myelography and CT myelography. *Eur Neurol*; 32(1): 11-16, 1992.
47. Chamberlain MC. Comparative spine imaging in leptomeningeal metastases. *J Neuro Oncol*; 23(3): 233-238, 1995.
48. Freilich RJ, Krol G, DeAngelis LM. Neuroimaging and cerebrospinal fluid cytology in the diagnosis of leptomeningeal metastasis. *Ann Neurol*; 38(1): 51-57, 1995.
49. Mittl RL, Jr., Yousem DM. Frequency of unexplained meningeal enhancement in the brain after lumbar puncture. *AJNR Am J Neuroradiol*; 15(4): 633-638, 1994.
50. Glantz MJ, Hall WA, Cole BF et al. Diagnosis, management, and survival of patients with leptomeningeal cancer based on cerebrospinal fluid-flow status. *Cancer*; 75(12): 2919-2931, 1995.
51. Trump DL, Grossman SA, Thompson G et al. CSF infections complicating the management of neoplastic meningitis. Clinical features and results of therapy. *Arch Intern Med*; 142(3): 583-586, 1982.
52. Chamberlain MC, Kormanik PA. Prognostic significance of 111indium-DTPA CSF flow studies in leptomeningeal metastases. *Neurology*; 46(6): 1674-1677, 1996.

53. Mason WP, Yeh SD, DeAngelis LM. 111Indium-diethylenetriamine pentaacetic acid cerebrospinal fluid flow studies predict distribution of intrathecally administered chemotherapy and outcome in patients with leptomeningeal metastases. *Neurology*; 50(2): 438-444, 1998.
54. Chamberlain MC, Corey-Bloom J. Leptomeningeal metastases: 111indium-DTPA CSF flow studies. *Neurology*; 41(11): 1765-1769, 1991.
55. Chamberlain MC, Kormanik P, Jaeckle KA et al. 111Indium-diethylenetriamine pentaacetic acid CSF flow studies predict distribution of intrathecally administered chemotherapy and outcome in patients with leptomeningeal metastases. *Neurology*; 52(1): 216-217, 1999.
56. Hildebrand J. Prophylaxis and treatment of leptomeningeal carcinomatosis in solid tumors of adulthood. *J Neuro Oncol*; 38(2-3): 193-198, 1998.
57. Chamberlain MC, Kormanik PA. Prognostic significance of coexistent bulky metastatic central nervous system disease in patients with leptomeningeal metastases. *Arch Neurol*; 54(11): 1364-1368, 1997.
58. Shapiro WR, Young DF, Mehta BM. Methotrexate: distribution in cerebrospinal fluid after intravenous, ventricular and lumbar injections. *N Engl J Med*; 293(4): 161-166, 1975.
59. Berweiler U, Krone A, Tonn JC. Reservoir systems for intraventricular chemotherapy. *J Neuro Oncol*; 38(2-3): 141-143, 1998.
60. Sandberg DI, Bilsky MH, Souweidane MM et al. Ommaya reservoirs for the treatment of leptomeningeal metastases. *Neurosurgery*; 47(1): 49-54, 2000.
61. Sause WT, Crowley J, Eyre HJ et al. Whole brain irradiation and intrathecal methotrexate in the treatment of solid tumor leptomeningeal metastases--a Southwest Oncology Group study. *J Neuro Oncol*; 6(2): 107-112, 1988.
62. Chamberlain MC, Kormanik P. Carcinoma meningitis secondary to non-small cell lung cancer: combined modality therapy. *Arch Neurol*; 55(4): 506-512, 1998.
63. Siegal T. Leptomeningeal metastases: rationale for systemic chemotherapy or what is the role of intra-CSF-chemotherapy? *J Neuro Oncol*; 38(2-3): 151-157, 1998.
64. Giannone L, Greco FA, Hainsworth JD. Combination intraventricular chemotherapy for meningeal neoplasia. *J Clin Oncol*; 4(1): 68-73, 1986.
65. Hitchins RN, Bell DR, Woods RL et al. A prospective randomized trial of single-agent versus combination chemotherapy in meningeal carcinomatosis. *J Clin Oncol*; 5(10): 1655-1662, 1987.
66. Bleyer WA, Drake JC, Chabner BA. Neurotoxicity and elevated cerebrospinal-fluid methotrexate concentration in meningeal leukemia. *N Engl J Med*; 289(15): 770-773, 1973.
67. Glantz MJ, Jaeckle KA, Chamberlain MC et al. A randomized controlled trial comparing intrathecal sustained-release cytarabine (DepoCyt) to intrathecal methotrexate in patients with neoplastic meningitis from solid tumors. *Clin Cancer Res*; 5(11): 3394-3402, 1999.
68. Siegal T, Pfeffer MR, Steiner I. Antibiotic therapy for infected Ommaya reservoir systems. *Neurosurgery*; 22(1 Pt 1): 97-100, 1988.
69. Kerr JZ, Berg S, Blaney SM. Intrathecal chemotherapy. *Crypt Rev Oncol Hematol*; 37(3): 227-236, 2001.

70. Bokstein F, Lossos A, Siegal T. Leptomeningeal metastases from solid tumors: a comparison of two prospective series treated with and without intra-cerebrospinal fluid chemotherapy. *Cancer*; 82(9): 1756-1763, 1998.
71. Glantz MJ, Cole BF, Recht L et al. High-Dose Intravenous Methotrexate for Patients with Nonleukemic Leptomeningeal Cancer: Is Intrathecal Chemotherapy Necessary? *J Clin Oncol*; 16(4): 1561-1567, 1998.
72. Boogerd W, Dorresteijn LDA, van der Sande JJ et al. Response of leptomeningeal metastases from breast cancer to hormonal therapy. *Neurology*; 55:117-119, 2000.
73. Blaney SM, Poplack DG. New cytotoxic drugs for intrathecal administration. *Journal of Neuro-Oncology*; 38:219-223, 1998.
74. Sampson JH, Archer GE, Villavicencio AT et al. Treatment of Neoplastic Meningitis with Intrathecal Temozolomide. *Clin Cancer Res*; 5:1183-1188, 1999.
75. Herrlinger U, Weller M, Schabet M. New aspects of immunotherapy of leptomeningeal metastasis. *Journal of Neuro-Oncology*; 38:233-239, 1998.
76. Coakham HB, Kemshead JT. Treatment of neoplastic meningitis by targeted radiation using <sup>131</sup>I-radiolabelled monoclonal antibodies. *Journal of Neuro-Oncology*; 38:225-232, 1998.
77. Vrionis FD. Gene Therapy of Neoplastic Meningiomas. *Journal of Neuro-Oncology*; 38:241-244, 1998.
78. Theodore WH, Gendelman S. Meningeal carcinomatosis. *Arch Neurol*; 38(11): 696-699, 1981.
79. Olson ME, Chernik NL, Posner JB. Infiltration of the leptomeninges by systemic cancer. A clinical and pathologic study. *Arch Neurol*; 30(2): 122-137, 1974.
80. Chamberlain MC. Combined Modality Treatment of Leptomeningeal Gliomatosis. *Neurosurgery* 52:324-330, 2003.
81. Glass J, Melamed M, Chernik N, et al. Malignant Cells in Cerebrospinal Fluid (CSF) The Meaning of a Positive CSF Cytology. *Neurology* 1979, 29:1369-1375.
82. Glantz MJ, LaFollette S, Jaeckle KA, Shapiro W, Swinnen L, Rozental JR, Phuphanich S, Rogers LR, Gutheil JC, Batchelor T, Lyter D, Chamberlain M, Maria BL, Schiffer C, Bashir R, Thomas D, Cowpens W, Howell SB. Randomized Trial of a Slow Release Versus a Standard Formulation of Cytarabine for the Intrathecal Treatment of Lymphomatous Meningitis. *J Clin Oncol* 1999, 17:3110-3116.
83. Chamberlain MC. Neoplastic meningitis-related encephalopathy: prognostic significance. *Neurology* 60(5): A17-18, 2003.
84. Jaeckle KA, Batchelor T, O'Day SJ, Phuphanich S, New P, Lesser G, Cohn A, Gilbert M, Aiken R, Heros D, Rogers L, Wong E, Fulton D, Gutheil J, Baidas S, Kennedy JM, Mason W, Moots P, Russell C, Swinnen LJ, Howell SB. *J Neuro-Oncol* 2002, 57(3): 231-239.
85. Chamberlain MC, Kormanik PA, Barba D. Complications associated with intraventricular chemotherapy in patients with leptomeningeal metastases. *Journal of Neurosurgery* 87:694-699, 1997.



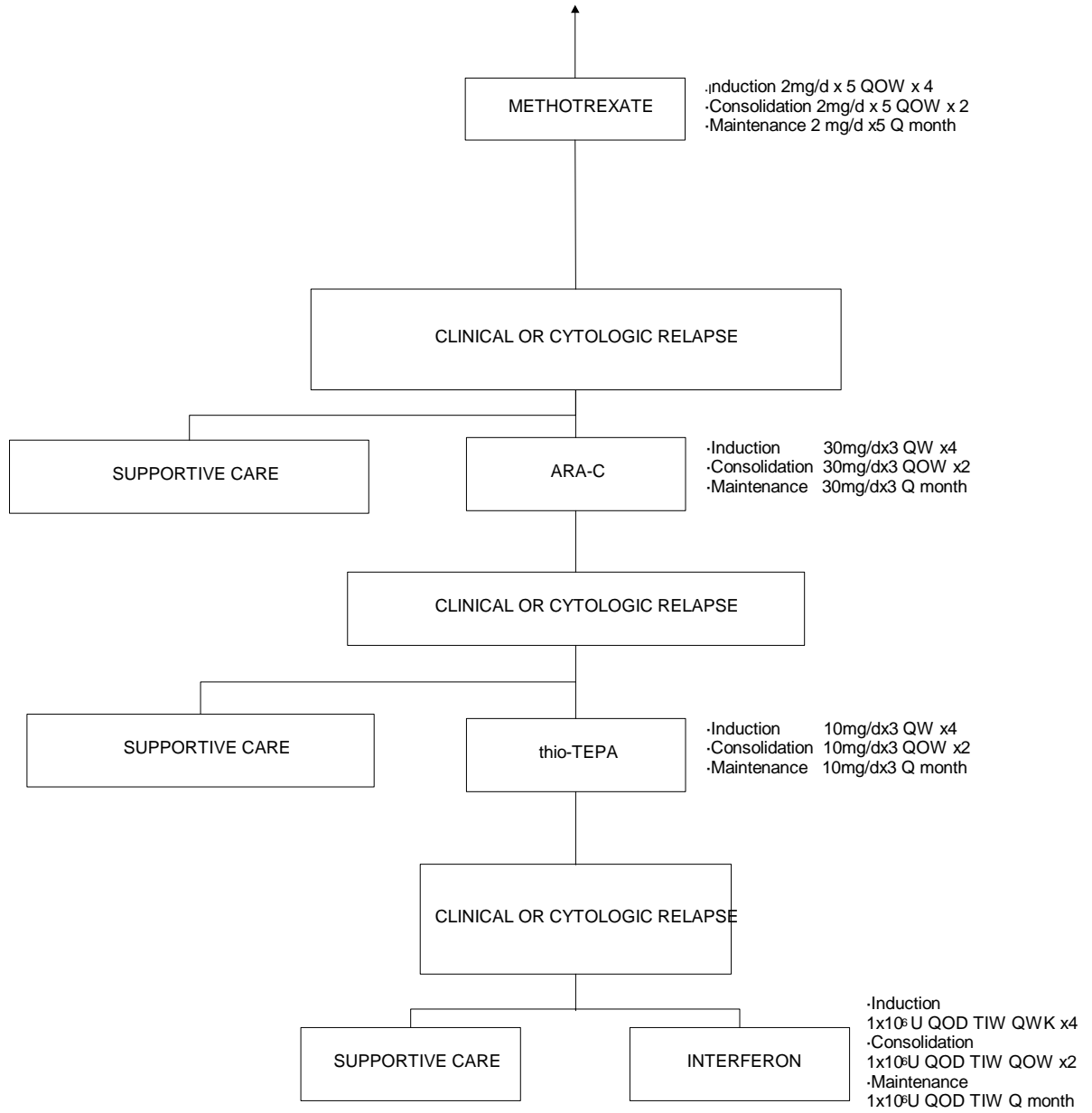


Table 1. Most Frequent Primary Tumors <sup>3,7,8</sup>.

Primary Site of Cancer	Percent
Breast cancer	27-50%
Lung cancer	22-36%
Adenocarcinoma	50-56%
Squamous cell carcinoma	26-36%
Small cell carcinoma	13-14%
Malignant melanoma	12%
Genitourinary	5%
Head and Neck	2%
Adenocarcinoma of Unknown Primary	2%

Table 2. Prognosis by Tumor Histology<sup>20,52,62, 80</sup>

Tumor Histology	Median Survival (Months)	Range (Months)
Breast (N=32) <sup>20</sup>	7.5	1.5 to 16
Non-Small Cell Lung Cancer (N=32) <sup>62</sup>	5	1 to 12
Melanoma (N=16) <sup>52</sup>	4	2 to 8
High-grade glioma (N=20) <sup>80</sup>	3.5	1-6

Table 3. Regional Chemotherapy for Neoplastic Meningitis.

Drugs	Induction Regimens		Consolidation Regimen		Maintenance regimen	
	Bolus Regimen	CxT Regimen	Bolus Regimen	CxT Regimen	Bolus Regimen	CxT Regimen
Methotrexate	10-15mg twice weekly (Total 4 weeks)	2mg/day for 5 days every other week (Total 8 weeks)	10-15mg once weekly (total 4 weeks)	2mg/day for 5 days every other week (total 4 weeks)	10-15mg once a month	2mg/day for 5 days once a month
Cytarabine	25-100mg 2 or 3 times weekly (Total 4 weeks)	25mg/day for 3 days weekly (Total 4 weeks)	25-100mg once weekly (Total 4 weeks)	25mg/day for 3 days every other week (Total 4 weeks)	25-100mg once a month	25mg/day for 3 days once a month
DepoCyt®	50mg every 2 weeks (Total 8 weeks)		50mg every 4 weeks (Total 24 weeks)			
Thiotepa	10mg 2 or 3 times weekly (Total 4 weeks)	10mg/day for 3 days weekly (total 4 weeks)	10mg once weekly (Total 4 weeks)	10mg/day for 3 days every other week (Total 4 weeks)	10mg once a month	10mg/day for 3 days once a month
$\alpha$ -Interferon	$1 \times 10^6$ u 3 times weekly (Total 4 weeks)		$1 \times 10^6$ u 3 times weekly every other week (Total 4 weeks)		$1 \times 10^6$ u 3 times weekly one week per month)	

